National Comprehensive Cancer Network®

NCCN Clinical Practice Guidelines in Oncology (NCCN Guidelines®)

Ampullary Adenocarcinoma

Version 2.2026 — February 10, 2026

NCCN recognizes the importance of clinical trials and encourages participation when applicable and available. Trials should be designed to maximize inclusiveness and broad representative enrollment.

Version 2.2026, 02/10/2026 © 2026 National Comprehensive Cancer Network® (NCCN®), All rights reserved. NCCN Guidelines® and this illustration may not be reproduced in any form without the express written permission of NCCN.

PLEASE NOTE that use of this NCCN Content is governed by the End-User License Agreement, and you MAY NOT distribute this Content or use it with any artificial intelligence model or tool.
Printed by Galya Basol Kochav on 2/14/2026 7:41:36 AM. Copyright © 2026 National Comprehensive Cancer Network, Inc. All Rights Reserved.

NCCN Guidelines Version 2.2026
Ampullary Adenocarcinoma

Andrew H. Ko, MD/Chair †
UCSF Helen Diller Family Comprehensive Cancer Center

Mokenge P. Malafa, MD/Vice Chair ¶
Moffitt Cancer Center

***E. Gabriela Chiorean, MD/Lead †**
Fred Hutchinson Cancer Center

***Marco Del Chiaro, MD, PhD/Co-Lead ¶**
University of Colorado Cancer Center

Olca Basturk, MD ≠
Memorial Sloan Kettering Cancer Center

Al B. Benson III, MD †
Robert H. Lurie Comprehensive Cancer Center of Northwestern University

Dana B. Cardin, MD †
Vanderbilt-Ingram Cancer Center

Jared A. Christensen, MD ф
University of Michigan Rogel Cancer Center

Vincent Chung, MD †
City of Hope National Medical Center

Brian Czito, MD §
Duke Cancer Institute

Mary Dillhoff, MD, MS ¶
The Ohio State University Comprehensive Cancer Center - James Cancer Hospital and Solove Research Institute

Timothy R. Donahue, MD ¶
UCLA Jonsson Comprehensive Cancer Center

Christos Fountzilas, MD ‡ †
Roswell Park Comprehensive Cancer Center

Jeffrey Hardacre, MD ¶
Case Comprehensive Cancer Center/ University Hospitals Seidman Cancer Center and Cleveland Clinic Taussig Cancer Institute

Kelsey Klute, MD †
Fred & Pamela Buffett Cancer Center

John W. Kunstman, MD, MHS ¶
Yale Cancer Center/Smilow Cancer Hospital

Kian-Huat Lim, MD, PhD †
Siteman Cancer Center at Barnes-Jewish Hospital and Washington University School of Medicine

Noelle LoConte, MD †
University of Wisconsin Carbone Cancer Center

Andrew M. Lowy, MD ¶
UC San Diego Moores Cancer Center

Ashiq Masood, MD ‡
Indiana University Melvin and Bren Simon Comprehensive Cancer Center

Cassadie Moravek, BS ¥
Pancreatic Cancer Action Network

Eric K. Nakakura, MD ¶
UCSF Helen Diller Family Comprehensive Cancer Center

Amol K. Narang, MD §
Johns Hopkins Kimmel Cancer Center

Lorenzo Nardo, MD, PhD ф ϕ
UC Davis Comprehensive Cancer Center

Jorge Obando, MD ¤
Duke Cancer Institute

Patricio M. Polanco, MD ¶
UT Southwestern Simmons Comprehensive Cancer Center

George Poultsides, MD, MS ¶
Stanford Cancer Institute

Sushanth Reddy, MD ¶
O'Neal Comprehensive Cancer Center at UAB

Marsha Reyngold, MD, PhD §
Memorial Sloan Kettering Cancer Center

Courtney Scaife, MD ¶
Huntsman Cancer Institute at the University of Utah

Ardaman Shergill, MD †
The UChicago Medicine Comprehensive Cancer Center

Mark J. Truty, MD, MS ¶
Mayo Clinic Comprehensive Cancer Center

Charles Vollmer Jr, MD ¶
Abramson Cancer Center at the University of Pennsylvania

David Weinberg, MD, MSc ¤
Fox Chase Cancer Center

Robert A. Wolff, MD †
The University of Texas MD Anderson Cancer Center

Brian M. Wolpin, MD, MPH †
Dana-Farber/Brigham and Women's Cancer Center

NCCN
Beth McCullough, RN, BS
Swathi Ramakrishnan, PhD
Sydney L. Roth, BS

ф Diagnostic/Interventional radiology
¤ Gastroenterology
‡ Hematology/Hematology oncology
† Medical oncology
ϕ Nuclear medicine
≠ Pathology
¥ Patient advocacy
§ Radiotherapy/Radiation oncology
¶ Surgery/Surgical oncology
* Discussion section writing committee

NCCN Guidelines Panel Disclosures

PLEASE NOTE that use of this NCCN Content is governed by the End-User License Agreement, and you MAY NOT distribute this Content or use it with any artificial intelligence model or tool.
Printed by Galya Basol Kochav on 2/14/2026 7:41:36 AM. Copyright © 2026 National Comprehensive Cancer Network, Inc. All Rights Reserved.

NCCN Guidelines Version 2.2026
Ampullary Adenocarcinoma

Ampullary Adenocarcinoma Panel Members
Summary of the Guidelines Updates

Clinical Suspicion of Ampullary Neoplasm (AMP-1)
Ampullary Adenoma (AMP-2)
Adenocarcinoma (AMP-3)
Localized Disease (AMP-4)
Postoperative Adjuvant Treatment (AMP-5)
Metastatic Disease (AMP-6)
Disease Progression (AMP-7)

Principles of Diagnosis, Imaging, and Staging (AMP-A)
Pancreatic Adenocarcinoma Radiology Reporting Template (AMP-A, 5 of 8)
Principles of Stent Management (AMP-B)
Principles of Surgical Technique (AMP-C)
Pathologic Analysis: Specimen Orientation, Histologic Sections, and Reporting (AMP-D)
Principles of Systemic Therapy (AMP-E)
Principles of Radiation Therapy (AMP-F)
Principles of Palliation and Supportive Care (AMP-G)

Staging (ST-1)

Abbreviations (ABBR-1)

Find an NCCN Member Institution: https://www.nccn.org/home/member-institutions.

NCCN Categories of Evidence and Consensus: All recommendations are category 2A unless otherwise indicated.

See NCCN Categories of Evidence and Consensus.

NCCN Categories of Preference: All recommendations are considered appropriate.

See NCCN Categories of Preference.

The NCCN Guidelines® are a statement of evidence and consensus of the authors regarding their views of currently accepted approaches to treatment. Any clinician seeking to apply or consult the NCCN Guidelines is expected to use independent medical judgment in the context of individual clinical circumstances to determine any patient's care or treatment. The National Comprehensive Cancer Network® (NCCN®) makes no representations or warranties of any kind regarding their content, use or application and disclaims any responsibility for their application or use in any way. The NCCN Guidelines are copyrighted by National Comprehensive Cancer Network®. All rights reserved. The NCCN Guidelines and the illustrations herein may not be reproduced in any form without the express written permission of NCCN. ©2026.

PLEASE NOTE that use of this NCCN Content is governed by the End-User License Agreement, and you MAY NOT distribute this Content or use it with any artificial intelligence model or tool.
Printed by Galya Basol Kochav on 2/14/2026 7:41:36 AM. Copyright © 2026 National Comprehensive Cancer Network, Inc. All Rights Reserved.

Updates in Version 2.2026 of the NCCN Guidelines for Ampullary Adenocarcinoma include:

MS-1
- The discussion section has been updated to reflect the changes in the algorithm.

Updates in Version 1.2026 of the NCCN Guidelines for Ampullary Adenocarcinoma include:

General
- References were updated throughout the guidelines.
- The NCCN Guidelines for the Management of Immunotherapy-Related Toxicities name changed to *NCCN Guidelines for the Management of Immune Checkpoint Inhibitor-Related Toxicities*.

AMP-3
- Footnote g revised: Core biopsy is recommended, if possible, to obtain adequate tissue for ~~possible~~ *molecular profiling or other* ancillary studies.
- Footnote h revised: Tumor/somatic molecular profiling*, preferably using a next-generation sequencing (NGS) assay,* is recommended for patients with ~~locally advanced~~/metastatic disease who are candidates for anti-cancer therapy to identify ~~uncommon mutations~~ *clinically actionable and/or emerging alterations, if clinically indicated.* ~~Consider specifically testing for potentially actionable somatic findings including~~ *These alterations include*, but *are* not limited to: ...tumor mutational burden (TMB) *using comprehensive genomic profiling* via an FDA-approved and/or validated ~~next-generation sequencing (~~NGS~~)~~ based assay *and HER2 overexpression via IHC ± FISH*. RNA sequencing assays are preferred for detecting RNA fusions because gene fusions are better detected by RNA-based NGS. Testing on tumor tissue is preferred; however, cell-free DNA testing can be considered if tumor tissue testing is not feasible. See Discussion. (Also AMP-6 and AMP-7)

AMP-4
- Treatment, Repeat pancreatic protocol CT or MRI, Footnote a added: Principles of Diagnosis, Imaging, and Staging (AMP-A).

AMP-5
- Postoperative Adjuvant Treatment, Resected ampullary cancer: Footnote p added.
- Footnote p revised: Initiation of adjuvant systemic therapy is recommended within 12 weeks of surgery if the patient is medically fit. ~~The optimal duration of treatment is 4 to 6 months.~~ *Patients who have received neoadjuvant chemoradiation or chemotherapy may be candidates for additional chemotherapy (or chemoradiation if none was delivered neoadjuvantly) following surgery and multidisciplinary review. The adjuvant therapy options are dependent on the response to neoadjuvant therapy and other clinical considerations. Total duration of systemic therapy is typically 6 months.*

AMP-6
- Metastatic disease
  - Good performance status (PS) revised: Good/*Intermediate* performance status (PS).
  - Poor PS: Footnote q added.
- Treatment, 2nd bullet: Footnote j added.
- Footnote q revised: *Good PS is* defined as ECOG 0–1~~,~~ with good biliary drainage and adequate nutritional intake*, intermediate PS is defined as ECOG 2, and poor PS is defined as ECOG 3.* (Also AMP-7)

AMP-7
- Disease Progression
  - Good performance status (PS) revised: Good/*Intermediate* performance status (PS).
  - Poor PS: Footnote q added.

AMP-A 1 of 8
- Principles of Diagnosis, Imaging, and Staging
  - 2nd bullet, last sentence removed: Imaging with contrast as appropriate for disease management (unless contraindicated).
  - 3rd bullet revised: Imaging should include dedicated pancreatic CT of abdomen *with contrast* (preferred) or MRI *with and without* contrast.

Version 2.2026, 02/10/2026 © 2026 National Comprehensive Cancer Network® (NCCN®), All rights reserved. NCCN Guidelines® and this illustration may not be reproduced in any form without the express written permission of NCCN.

PLEASE NOTE that use of this NCCN Content is governed by the End-User License Agreement, and you MAY NOT distribute this Content or use it with any artificial intelligence model or tool.
Printed by Galya Basol Kochav on 2/14/2026 7:41:36 AM. Copyright © 2026 National Comprehensive Cancer Network, Inc. All Rights Reserved.

Updates in Version 1.2026 of the NCCN Guidelines for Ampullary Adenocarcinoma include:

AMP-D 1 of 6
- Pathologic analysis: Specimen Orientation, Histologic Sections, and Reporting
  - Pancreatoduodenectomy
    - ◊ 1st bullet revised: There should be either direct communication between the surgeon and pathologist for proper orientation and margin identification, or the surgeon should identify the important margins with a clearly understood and documented method (eg, written on the pathology requisition*, such as the bile duct margin and, if present, the proximal and distal margins of the portal vein should be marked).*~~; for example: the distal and proximal margins of the SMV and SMA and the bile duct margin and, if present, the proximal and distal margins of the portal vein should be marked.~~
    - ◊ 2nd bullet, last sentence revised: ~~For optimal staging, a minimum of 17 lymph nodes in pancreatoduodenectomy specimens is recommended.~~ *Adequate lymph node assessment may be more challenging after neoadjuvant therapy, but the panel consensus is an assessment of at least 12 lymph nodes.*

AMP-D 2 of 6
- Pathologic analysis: Specimen Orientation, Histologic Sections, and Reporting
  - Pancreatoduodenectomy (continued), Margins, 1st bullet, 1st sub-bullet, revised: ...~~The uncinate margin should be inked. Rather than being submitted en face, the uncinate~~ *Therefore, the* margin tissue should be *inked*, shaved/amputated, and then ~~the portion of tissue should be~~ sectioned perpendicular to the ink and submitted entirely for histologic examination.

AMP-D 3 OF 6
- Pathologic analysis: Specimen Orientation, Histologic Sections, and Reporting
  - Pancreatoduodenectomy (continued), Other Circumferential Surfaces, 2nd bullet revised: Also referred to as the vascular groove*/vascular bed* surface, this is the smooth-surfaced groove on the posterior-medial surface of the pancreatic head that rests over the SMV...
  - Pancreatoduodenectomy (continued), Histologic Sectioning
    - ◊ 1st bullet revised: For *the* examination of ampullary carcinoma, it is recommended that the pancreas be bivalved along probes placed in the bile and pancreatic ducts~~,~~. *Each half should then be sectioned perpendicularly to the inked anterior and posterior surfaces, and sections should be submitted in a manner that allows for accurate assessment.* ~~with sections submitted in a manner that allows for determination~~ of the extent of invasion into the sphincter of Oddi, duodenal wall, and pancreas~~,~~. *This approach also helps determine* ~~as well as~~ the relationship between invasive carcinoma and any *associated* precursor lesions ~~from which it may be arising~~*, as well as its* ~~and the~~ relationship to the pancreatic circumferential tissue margins mentioned above
    - ◊ 2nd bullet added: Per the current College of American Pathologists (CAP) protocol, the presence of tumor at or within 1 mm of resection margin constitutes a positive margin, although this recommendation is based primarily on extrapolation of data on rectal adenocarcinoma. There is currently a lack of definitive evidence for what constitutes an adequate margin in ampullary carcinoma resection specimens.

AMP-E
- Principles of Systemic Therapy, General Principles
  - 10th bullet added: For information regarding DPYD testing, see the NCCN Guidelines for Colon Cancer.
  - 11th bullet moved from footnotes on AMP-E 3 of 11: Nivolumab and hyaluronidase-nvhy is not approved for concurrent use with IV Ipilimumab; however, for Nivolumab monotherapy, Nivolumab and hyaluronidase-nvhy subcutaneous injection may be substituted for IV Nivolumab. Nivolumab and hyaluronidase-nvhy has different dosing and administration instructions compared to IV Nivolumab. (Also AMP-E 4 of 11, AMP-E 5 of 11, AMP-E 6 of 11, and AMP-E 7 of 11)
  - 12th bullet added: Pembrolizumab and berahyaluronidase alfa-pmph subcutaneous injection may be substituted for IV Pembrolizumab. Pembrolizumab and berahyaluronidase alfa-pmph has different dosing and administration instructions compared to IV Pembrolizumab.

Version 2.2026, 02/10/2026 © 2026 National Comprehensive Cancer Network® (NCCN®), All rights reserved. NCCN Guidelines® and this illustration may not be reproduced in any form without the express written permission of NCCN.

PLEASE NOTE that use of this NCCN Content is governed by the End-User License Agreement, and you MAY NOT distribute this Content or use it with any artificial intelligence model or tool.
Printed by Galya Basol Kochav on 2/14/2026 7:41:36 AM. Copyright © 2026 National Comprehensive Cancer Network, Inc. All Rights Reserved.

Updates in Version 1.2026 of the NCCN Guidelines for Ampullary Adenocarcinoma include:

AMP-E 1 of 11
- Footnote e added to modified FOLFIRINOX: Due to the high toxicity of this regimen, bolus fluorouracil is often omitted. (Also AMP-E 2 of 11)

AMP-E 3 of 11
- This page was extensively revised.

AMP-E 4 of 11
- Principles of Systemic Therapy, Metastatic Disease (First-Line Therapy)
  - Footnote h added.
  - Poor PS revised: Poor PS *3* (Also AMP-E 7 of 11)
  - Pancreatobiliary/Mixed Type and Intestinal Type
    - ◊ 1st bullet added: Palliative and best supportive care, see NCCN Guidelines for Palliative Care. (Also AMP-E 7 of 11)
  - Targeted Systemic Therapies
    - ◊ Useful in Certain Circumstances, 3rd bullet added: Nivolumab (if MSI-H or dMMR, for intestinal type only).
- Footnote h added: Good PS is defined as ECOG 0–1~~,~~ with good biliary drainage and adequate nutritional intake, intermediate PS is defined as ECOG 2, and poor PS is defined as ECOG 3. (Also AMP-E 6 of 11 and AMP-E 7 of 11)

AMP-E 5 of 11
- Principles of Systemic Therapy, Therapy for Disease Progression
  - Footnote h added. (Also AMP-E 6 of 11 and AMP-E 7 of 11)
  - Good PS revised: Good PS *0-1.*
- Footnote h revised: *Good PS is* defined as ECOG 0–1~~,~~ with good biliary drainage and adequate nutritional intake*, intermediate PS is defined as ECOG 2, and poor PS is defined as ECOG 3.*

AMP-E 6 of 11
- Principles of Systemic Therapy, Therapy for Disease Progression
  - Pancreatobiliary/Mixed Type, Intestinal Type, and Targeted Systemic Therapies: Intermediate PS 2 added.

AMP-E 7 of 11
- This page was extensively revised.

AMP-F 1 of 6
- Principles of Radiation Therapy, General Principles, 2nd bullet revised: Prior to initiation of RT, staging is optimally determined with a ~~contrast-enhanced abdominal~~ CT *abdomen with contrast* ~~(3D conformal RT [3D-CRT])~~ and/or MRI *with and without contrast.*

AMP-F 2 of 6
- Principles of Radiation Therapy, Treatment Planning: Radiation Delivery, Simulation, 3rd bullet, last sentence revised: Neutral ~~oral~~ contrast may also be utilized.

Version 2.2026, 02/10/2026 © 2026 National Comprehensive Cancer Network® (NCCN®), All rights reserved. NCCN Guidelines® and this illustration may not be reproduced in any form without the express written permission of NCCN.

PLEASE NOTE that use of this NCCN Content is governed by the End-User License Agreement, and you MAY NOT distribute this Content or use it with any artificial intelligence model or tool.
Printed by Galya Basol Kochav on 2/14/2026 7:41:36 AM. Copyright © 2026 National Comprehensive Cancer Network, Inc. All Rights Reserved.

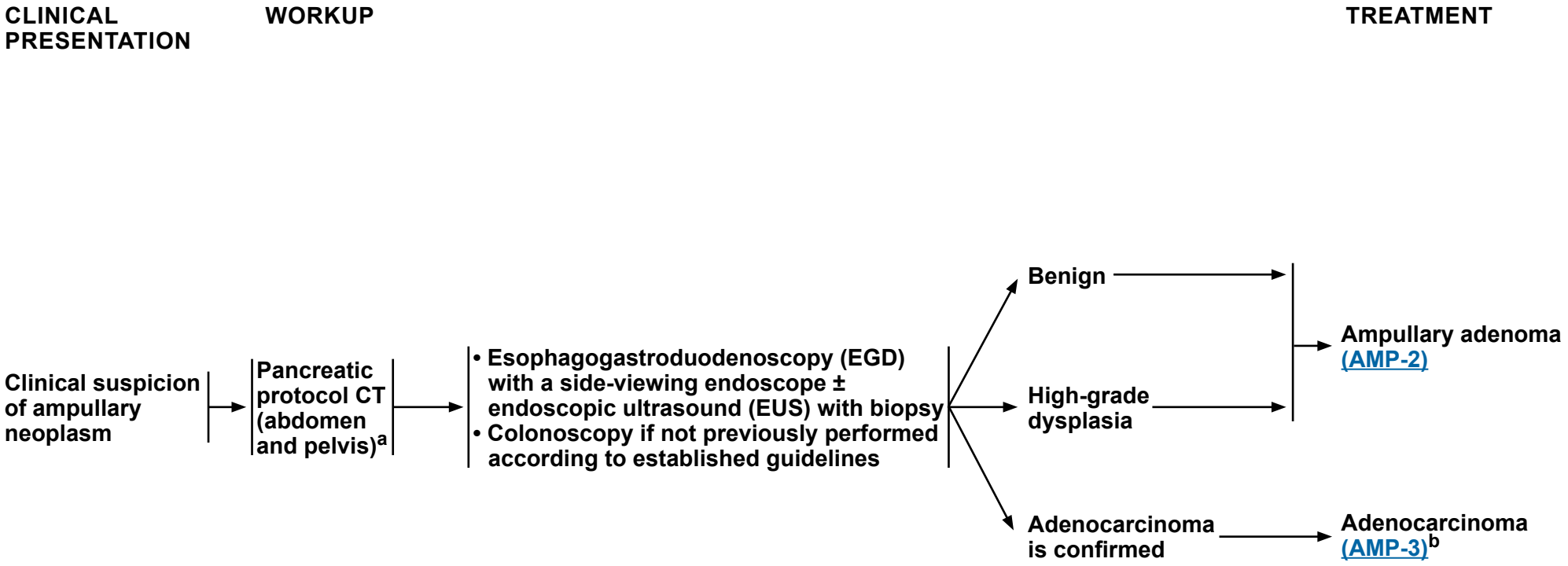

[a] Principles of Diagnosis, Imaging, and Staging (AMP-A).

[b] Genetic testing for inherited mutations is recommended for any patient with confirmed ampullary adenocarcinoma or positive family history of cancer, using comprehensive gene panels for hereditary cancer syndromes. Genetic counseling is recommended for patients who test positive for a pathogenic mutation (*ATM, BRCA1, BRCA2, CDKN2A, MLH1, MSH2, MSH6, PALB2, PMS2, STK11,* and *TP53*) or for patients with a positive family history of cancer, regardless of mutation status.

Note: All recommendations are category 2A unless otherwise indicated.

Version 2.2026, 02/10/2026 © 2026 National Comprehensive Cancer Network® (NCCN®), All rights reserved. NCCN Guidelines® and this illustration may not be reproduced in any form without the express written permission of NCCN.

PLEASE NOTE that use of this NCCN Content is governed by the End-User License Agreement, and you MAY NOT distribute this Content or use it with any artificial intelligence model or tool.
Printed by Galya Basol Kochav on 2/14/2026 7:41:36 AM. Copyright © 2026 National Comprehensive Cancer Network, Inc. All Rights Reserved.

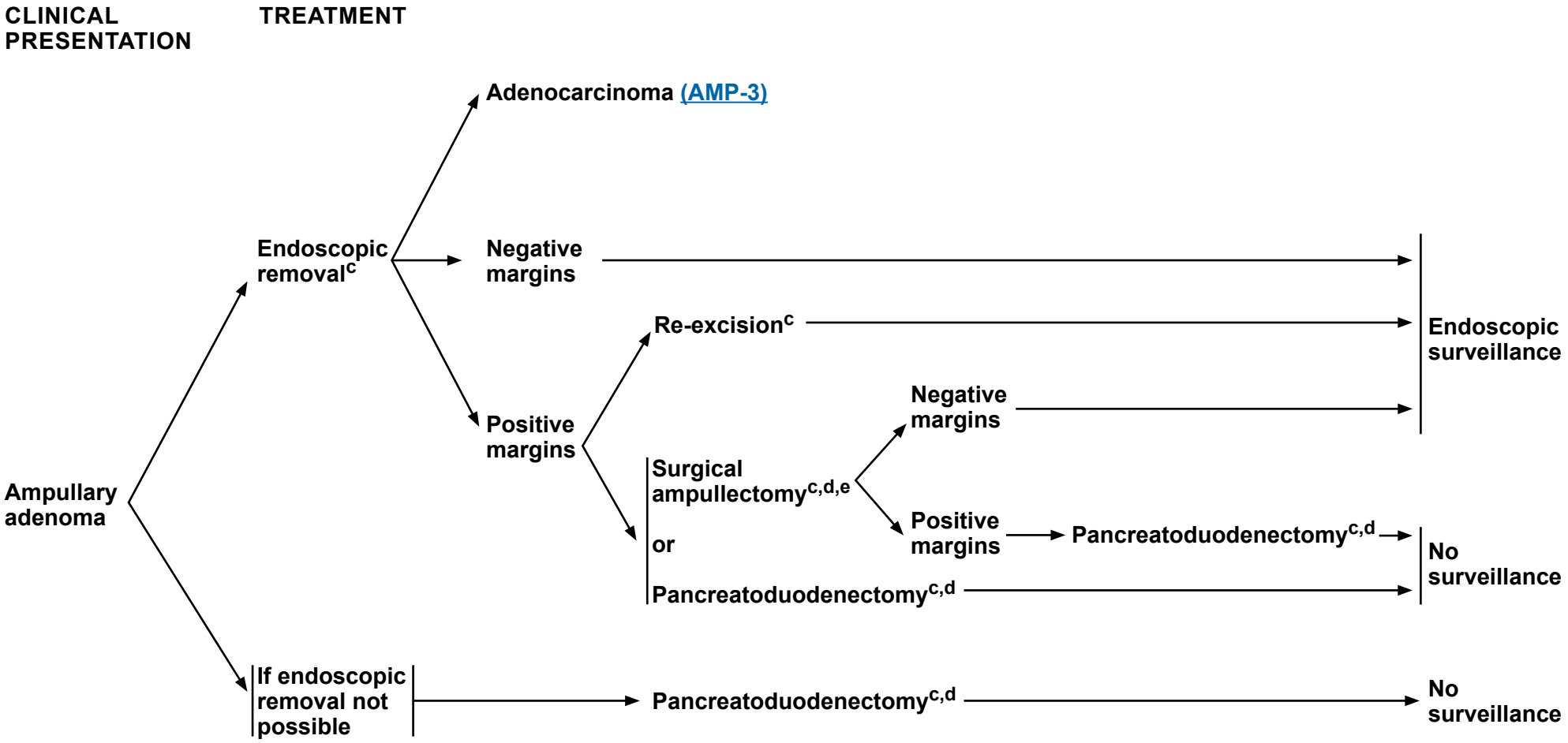

[c] Principles of Surgical Technique (AMP-C).
[d] Should be performed at a high-volume tertiary center.
[e] Ampullectomy can be chosen at surgical centers where there is expertise for this technique.

Note: All recommendations are category 2A unless otherwise indicated.

Version 2.2026, 02/10/2026 © 2026 National Comprehensive Cancer Network® (NCCN®), All rights reserved. NCCN Guidelines® and this illustration may not be reproduced in any form without the express written permission of NCCN.

PLEASE NOTE that use of this NCCN Content is governed by the End-User License Agreement, and you MAY NOT distribute this Content or use it with any artificial intelligence model or tool.
Printed by Galya Basol Kochav on 2/14/2026 7:41:36 AM. Copyright © 2026 National Comprehensive Cancer Network, Inc. All Rights Reserved.

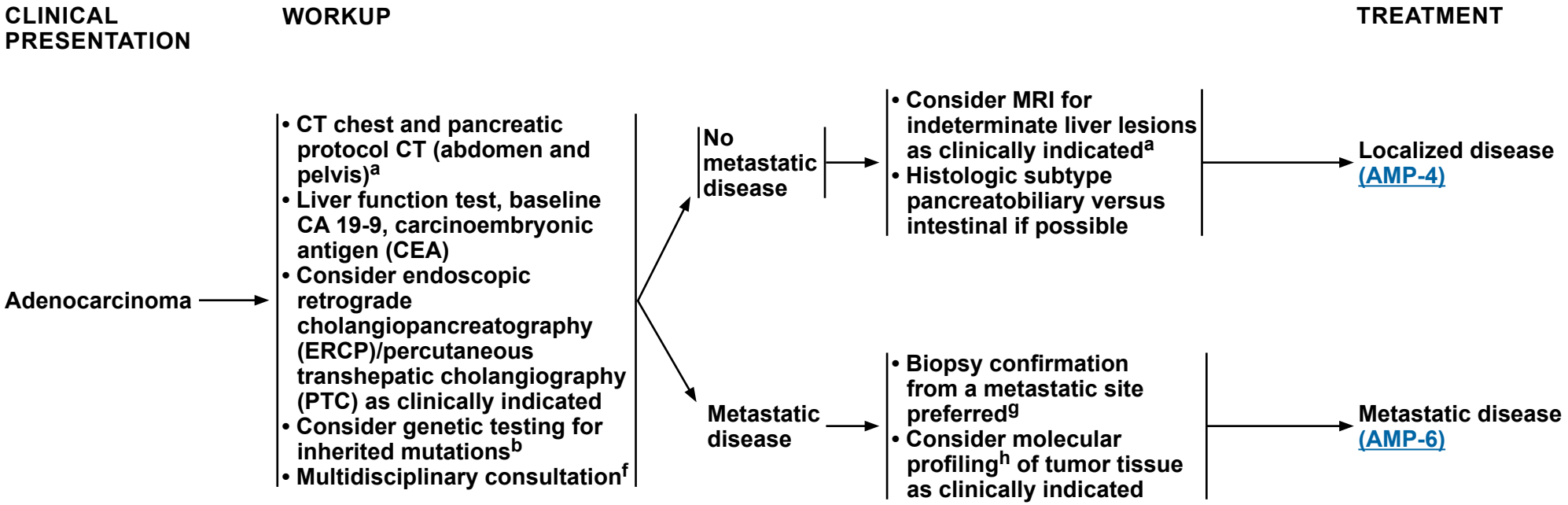

[a] Principles of Diagnosis, Imaging, and Staging (AMP-A).
[b] Genetic testing for inherited mutations is recommended for any patient with confirmed ampullary adenocarcinoma or positive family history of cancer, using comprehensive gene panels for hereditary cancer syndromes. Genetic counseling is recommended for patients who test positive for a pathogenic mutation (*ATM, BRCA1, BRCA2, CDKN2A, MLH1, MSH2, MSH6, PALB2, PMS2, STK11,* and *TP53*) or for patients with a positive family history of cancer, regardless of mutation status.
[f] Multidisciplinary review should consider involving expertise from diagnostic imaging, interventional endoscopy, medical oncology, radiation oncology, surgery, pathology, geriatric medicine, genetic counseling, and palliative care (Principles of Palliation and Supportive Care [AMP-G]). Consider consultation with a registered dietitian. See NCCN Guidelines for Older Adult Oncology and NCCN Guidelines for Palliative Care.
[g] Core biopsy is recommended, if possible, to obtain adequate tissue for molecular profiling or other ancillary studies.
[h] Tumor/somatic molecular profiling, preferably using a next-generation sequencing (NGS) assay, is recommended for patients with metastatic disease who are candidates for anti-cancer therapy, to identify clinically actionable and/or emerging alterations, if clinically indicated. These alterations include, but are not limited to: fusions (*ALK, NRG1, NTRK, ROS1, FGFR2,* and *RET*), mutations (*BRAF, BRCA1/2, KRAS,* and *PALB2*), amplifications (*HER2*), microsatellite instability (MSI), mismatch repair deficiency (dMMR), or tumor mutational burden (TMB) using comprehensive genomic profiling via an FDA-approved and/or validated NGS-based assay and *HER2* overexpression via immunohistochemistry (IHC) ± fluorescence in situ hybridization (FISH). RNA sequencing assays are preferred for detecting RNA fusions because gene fusions are better detected by RNA-based NGS. Testing on tumor tissue is preferred; however, cell-free DNA testing can be considered if tumor tissue testing is not feasible. See Discussion.

Note: All recommendations are category 2A unless otherwise indicated.

Version 2.2026, 02/10/2026 © 2026 National Comprehensive Cancer Network® (NCCN®), All rights reserved. NCCN Guidelines® and this illustration may not be reproduced in any form without the express written permission of NCCN.

PLEASE NOTE that use of this NCCN Content is governed by the End-User License Agreement, and you MAY NOT distribute this Content or use it with any artificial intelligence model or tool.
Printed by Galya Basol Kochav on 2/14/2026 7:41:36 AM. Copyright © 2026 National Comprehensive Cancer Network, Inc. All Rights Reserved.

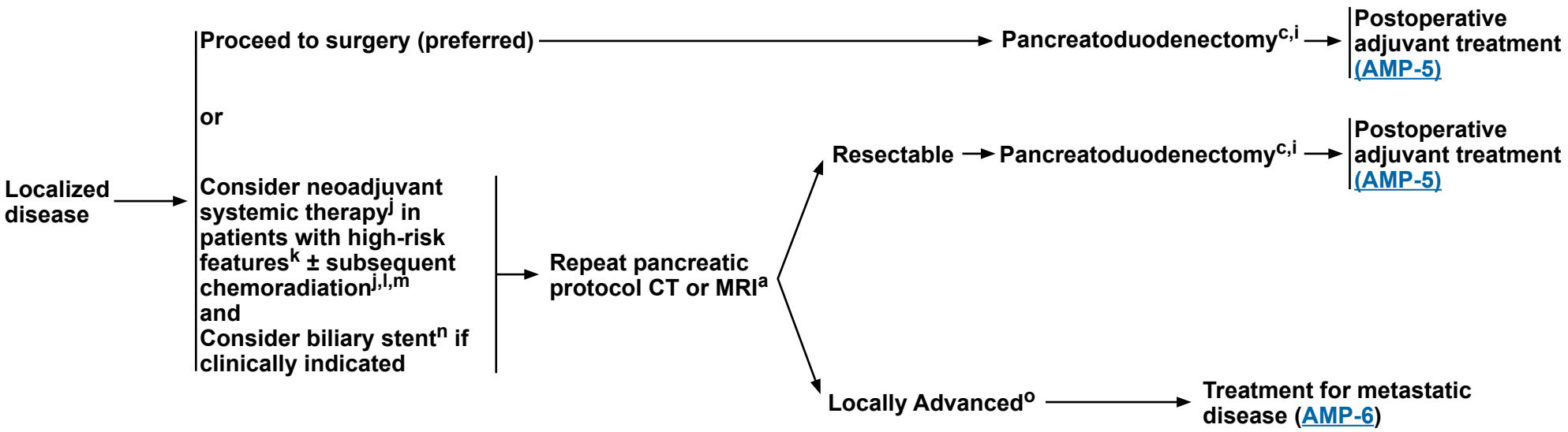

[a] Principles of Diagnosis, Imaging, and Staging (AMP-A).
[c] Principles of Surgical Technique (AMP-C).
[i] Pathologic Analysis: Specimen Orientation, Histologic Sections, and Reporting (AMP-D).
[j] Principles of Systemic Therapy (AMP-E).
[k] High-risk features include equivocal or indeterminate imaging findings, markedly elevated CA 19-9, markedly elevated CEA, large primary tumors, large regional lymph nodes, excessive weight loss, and extreme pain.
[l] There is limited evidence to recommend specific neoadjuvant regimens off-study, and practices vary with regard to the use of chemotherapy and chemoradiation.
[m] Principles of Radiation Therapy (AMP-F).
[n] Principles of Stent Management (AMP-B).
[o] Refer to tertiary cancer center for second opinion about unresectability.

Note: All recommendations are category 2A unless otherwise indicated.

Version 2.2026, 02/10/2026 © 2026 National Comprehensive Cancer Network® (NCCN®), All rights reserved. NCCN Guidelines® and this illustration may not be reproduced in any form without the express written permission of NCCN.

PLEASE NOTE that use of this NCCN Content is governed by the End-User License Agreement, and you MAY NOT distribute this Content or use it with any artificial intelligence model or tool.
Printed by Galya Basol Kochav on 2/14/2026 7:41:36 AM. Copyright © 2026 National Comprehensive Cancer Network, Inc. All Rights Reserved.

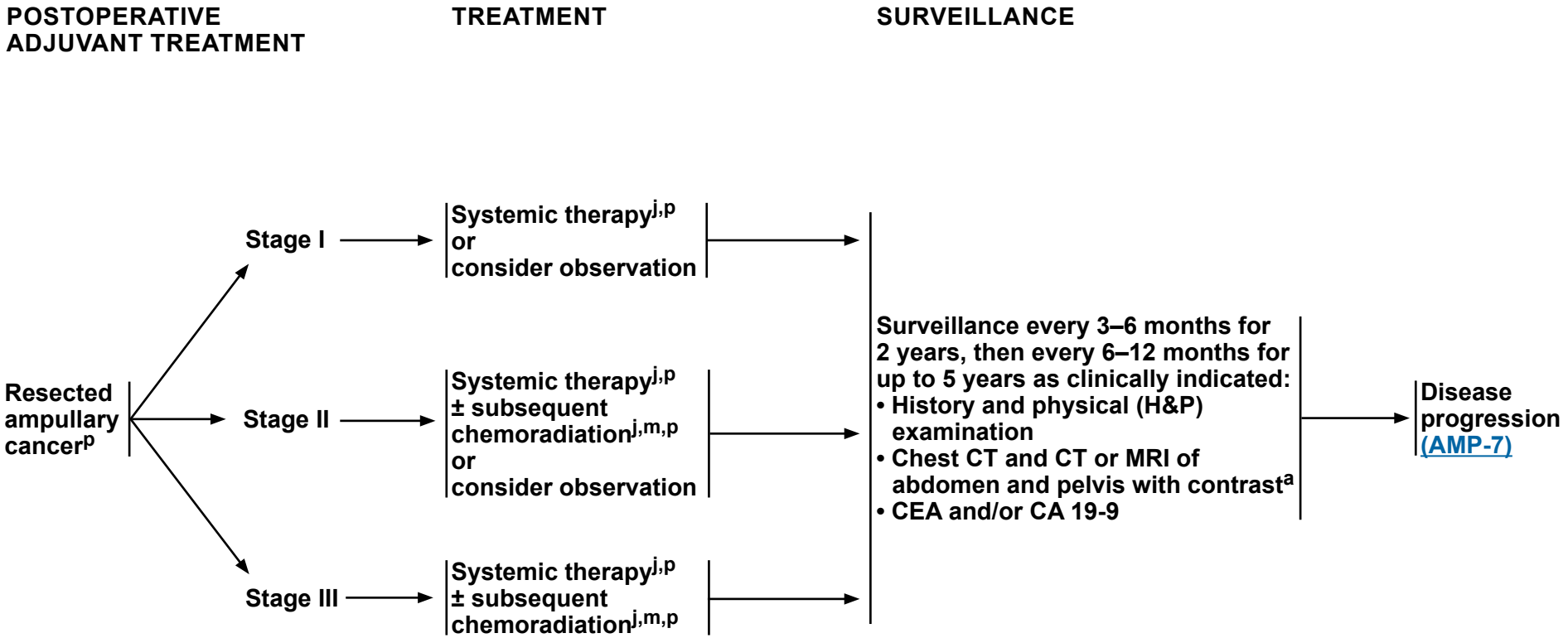

[a] Principles of Diagnosis, Imaging, and Staging (AMP-A).
[j] Principles of Systemic Therapy (AMP-E).
[m] Principles of Radiation Therapy (AMP-F).
[p] Initiation of adjuvant systemic therapy is recommended within 12 weeks of surgery if the patient is medically fit. Patients who have received neoadjuvant chemoradiation or chemotherapy may be candidates for additional chemotherapy (or chemoradiation if none was delivered neoadjuvantly) following surgery and multidisciplinary review. The adjuvant therapy options are dependent on the response to neoadjuvant therapy and other clinical considerations. Total duration of systemic therapy is typically 6 months.

Note: All recommendations are category 2A unless otherwise indicated.

Version 2.2026, 02/10/2026 © 2026 National Comprehensive Cancer Network® (NCCN®), All rights reserved. NCCN Guidelines® and this illustration may not be reproduced in any form without the express written permission of NCCN.

PLEASE NOTE that use of this NCCN Content is governed by the End-User License Agreement, and you MAY NOT distribute this Content or use it with any artificial intelligence model or tool.
Printed by Galya Basol Kochav on 2/14/2026 7:41:36 AM. Copyright © 2026 National Comprehensive Cancer Network, Inc. All Rights Reserved.

METASTATIC DISEASE

TREATMENT

Metastatic disease →

- **Genetic testing for inherited mutations, if not previously done[b]**
- **Molecular profiling of tumor tissue, if not previously performed[h]**

→ **Good/ Intermediate performance status (PS)[q]** →

Systemic therapy[j]
or
Consider targeted therapy[j] based on molecular profiling as clinically indicated
or
Systemic therapy[j] followed by radiation therapy (RT)[m] for palliative indications
or
Systemic therapy[j] followed by surgery or other locally directed therapies to liver or lung metastases for select patients with oligometastatic disease and response/ stable disease to systemic therapy

→ **Disease progression (AMP-7)**

→ **Poor PS[q]** →

Palliative and best supportive care[r]
and
Consider systemic therapy[j]
or
Consider targeted therapy[j] based on molecular profiling[h] as clinically indicated
or
Palliative RT[m]

[b] Genetic testing for inherited mutations is recommended for any patient with confirmed ampullary adenocarcinoma or positive family history of cancer, using comprehensive gene panels for hereditary cancer syndromes. Genetic counseling is recommended for patients who test positive for a pathogenic mutation (*ATM, BRCA1, BRCA2, CDKN2A, MLH1, MSH2*, *MSH6, PALB2, PMS2, STK11,* and *TP53*) or for patients with a positive family history of cancer, regardless of mutation status.
[h] Tumor/somatic molecular profiling, preferably using a NGS assay, is recommended for patients with metastatic disease who are candidates for anti-cancer therapy to identify clinically actionable and/or emerging alterations, if clinically indicated. These alterations include, but are not limited to: fusions (*ALK, NRG1, NTRK, ROS1, FGFR2,* and *RET*), mutations (*BRAF, BRCA1/2, KRAS,* and *PALB2*), amplifications (*HER2*), MSI, dMMR, or TMB using comprehensive genomic profiling via an FDA-approved and/or validated NGS-based assay and *HER2* overexpression via IHC ± FISH. RNA sequencing assays are preferred for detecting RNA fusions because gene fusions are better detected by RNA-based NGS. Testing on tumor tissue is preferred; however, cell-free DNA testing can be considered if tumor tissue testing is not feasible. See Discussion.
[j] Principles of Systemic Therapy (AMP-E).
[m] Principles of Radiation Therapy (AMP-F).
[q] Good PS is defined as ECOG 0–1 with good biliary drainage and adequate nutritional intake, intermediate PS is defined as ECOG 2, and poor PS is defined as ECOG 3.
[r] Principles of Palliation and Supportive Care (AMP-G).

Note: All recommendations are category 2A unless otherwise indicated.

Version 2.2026, 02/10/2026 © 2026 National Comprehensive Cancer Network® (NCCN®), All rights reserved. NCCN Guidelines® and this illustration may not be reproduced in any form without the express written permission of NCCN.

PLEASE NOTE that use of this NCCN Content is governed by the End-User License Agreement, and you MAY NOT distribute this Content or use it with any artificial intelligence model or tool.
Printed by Galya Basol Kochav on 2/14/2026 7:41:36 AM. Copyright © 2026 National Comprehensive Cancer Network, Inc. All Rights Reserved.

DISEASE PROGRESSION

SUBSEQUENT THERAPY[a,s]

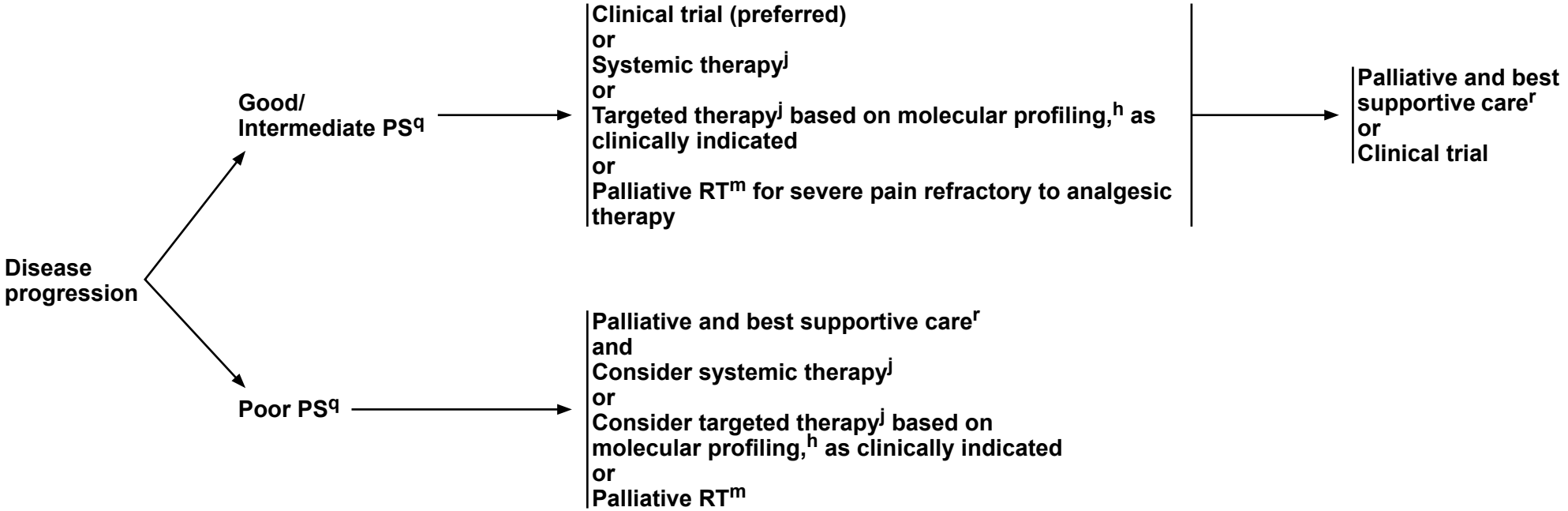

[a] Principles of Diagnosis, Imaging, and Staging (AMP-A).
[h] Tumor/somatic molecular profiling, preferably using a NGS assay, is recommended for patients with metastatic disease who are candidates for anti-cancer therapy to identify clinically actionable and/or emerging alterations, if clinically indicated. These alterations include, but are not limited to: fusions (*ALK, NRG1, NTRK, ROS1, FGFR2,* and *RET*), mutations (*BRAF, BRCA1/2, KRAS,* and *PALB2*), amplifications (*HER2*), MSI, dMMR, or TMB using comprehensive genomic profiling via an FDA-approved and/or validated NGS-based assay and *HER2* overexpression via IHC ± FISH. RNA sequencing assays are preferred for detecting RNA fusions because gene fusions are better detected by RNA-based NGS. Testing on tumor tissue is preferred; however, cell-free DNA testing can be considered if tumor tissue testing is not feasible. See Discussion.
[j] Principles of Systemic Therapy (AMP-E).
[m] Principles of Radiation Therapy (AMP-F).
[q] Good PS is defined as ECOG 0–1 with good biliary drainage and adequate nutritional intake, intermediate PS is defined as ECOG 2, and poor PS is defined as ECOG 3.
[r] Principles of Palliation and Supportive Care (AMP-G).
[s] Serial imaging as indicated to assess disease response.

Note: All recommendations are category 2A unless otherwise indicated.

Version 2.2026, 02/10/2026 © 2026 National Comprehensive Cancer Network® (NCCN®), All rights reserved. NCCN Guidelines® and this illustration may not be reproduced in any form without the express written permission of NCCN.

PLEASE NOTE that use of this NCCN Content is governed by the End-User License Agreement, and you MAY NOT distribute this Content or use it with any artificial intelligence model or tool.
Printed by Galya Basol Kochav on 2/14/2026 7:41:36 AM. Copyright © 2026 National Comprehensive Cancer Network, Inc. All Rights Reserved.

PRINCIPLES OF DIAGNOSIS, IMAGING, AND STAGING

- Decisions about diagnostic management and resectability should involve multidisciplinary consultation at a high-volume center with reference to appropriate high-quality imaging studies to evaluate the extent of disease. Resections should be done at institutions that perform a large number (at least 15–20) of pancreatic resections and/or endoscopic and surgical ampullectomy annually.

- High-quality dedicated imaging of the ampullary region should be performed at presentation (even if standard CT imaging is already available), preferably within 4 weeks of surgery, and following neoadjuvant treatment to provide adequate staging and assessment of resectability status. Imaging should be done prior to stenting, when possible.

- Imaging should include dedicated pancreatic CT of abdomen with contrast (preferred) or MRI with and without contrast.
  - Multi-detector CT (MDCT) angiography, performed by acquiring thin, preferably submillimeter, axial sections using a dual-phase pancreatic protocol, with images obtained in the pancreatic and portal venous phase of contrast enhancement, is the preferred imaging tool for dedicated pancreatic imaging.[a] Scan coverage can be extended to cover the chest and pelvis for complete staging as per institutional preferences. Multiplanar reconstruction is preferred as it allows precise visualization of the relationship of the primary tumor to the mesenteric vasculature as well as detection of subcentimeter metastatic deposits. See MDCT Pancreatic Adenocarcinoma Protocol, AMP-A (3 of 8).
  - MRI is most commonly used as a problem-solving tool, particularly for characterization of CT-indeterminate liver lesions or when contrast-enhanced CT cannot be obtained (as in cases with severe allergy to iodinated intravenous [IV] contrast material). This preference for using MDCT as the main imaging tool in many hospitals and imaging centers is mainly due to the higher cost and lack of widespread availability of MRI compared to CT. See MRI Pancreatic Adenocarcinoma Protocol, AMP-A (4 of 8).

- The decision regarding resectability status should be made by consensus at multidisciplinary meetings/discussions following the acquisition of dedicated ampullary imaging including complete staging. Use of a radiology staging reporting template is preferred to ensure complete assessment and reporting of all imaging criteria essential for optimal staging, which will improve the decision-making process.[a] See Pancreatic Cancer Radiology Reporting Template, AMP-A (5 of 8). This template can also be used for ampullary tumors.

[a] Al-Hawary MM, Francis IR, Chari ST, et al. Pancreatic ductal adenocarcinoma radiology reporting template: consensus statement of the Society of Abdominal Radiology and the American Pancreatic Association. Radiology 2014;270:248-260.

Note: All recommendations are category 2A unless otherwise indicated.

Version 2.2026, 02/10/2026 © 2026 National Comprehensive Cancer Network® (NCCN®), All rights reserved. NCCN Guidelines® and this illustration may not be reproduced in any form without the express written permission of NCCN.

PLEASE NOTE that use of this NCCN Content is governed by the End-User License Agreement, and you MAY NOT distribute this Content or use it with any artificial intelligence model or tool.
Printed by Galya Basol Kochav on 2/14/2026 7:41:36 AM. Copyright © 2026 National Comprehensive Cancer Network, Inc. All Rights Reserved.

PRINCIPLES OF DIAGNOSIS, IMAGING, AND STAGING

- The role of PET/CT (without iodinated IV contrast) remains unclear. Diagnostic CT or MRI with IV contrast as discussed above in conjunction with functional PET imaging can be used per institutional preference. It is not a substitute for high-quality, contrast-enhanced CT.
- EUS is recommended as an adjunct to EGD for benign adenomas, high-grade dysplasia, and invasive carcinoma to assess resectability by an endoscopic approach or by surgical ampullectomy and to exclude pancreatic invasion, which would mandate pancreatoduodenectomy.
- Colonoscopy should be performed to exclude synchronous colonic polyps or neoplasms according to established guidelines.
- Consider diagnostic staging laparoscopy to rule out metastases not detected on imaging as an option prior to surgery or chemoradiation.

Note: All recommendations are category 2A unless otherwise indicated.

Version 2.2026, 02/10/2026 © 2026 National Comprehensive Cancer Network® (NCCN®), All rights reserved. NCCN Guidelines® and this illustration may not be reproduced in any form without the express written permission of NCCN.

PLEASE NOTE that use of this NCCN Content is governed by the End-User License Agreement, and you MAY NOT distribute this Content or use it with any artificial intelligence model or tool.
Printed by Galya Basol Kochav on 2/14/2026 7:41:36 AM. Copyright © 2026 National Comprehensive Cancer Network, Inc. All Rights Reserved.

PRINCIPLES OF DIAGNOSIS, IMAGING, AND STAGING

MDCT Pancreatic Adenocarcinoma Protocol[b,c]

Parameters	Details
Scan type	Helical (preferably 64-multidetector row scanner or more)
Slice thickness	Thinnest possible (<3 mm). Preferably submillimeter (0.5–1 mm) if available
Interval	Same as slice thickness (no gap)
Oral contrast agent	Neutral contrast (positive oral contrast may compromise the three-dimensional [3D] and maximum intensity projection [MIP] reformatted images)
IV contrast	Iodine-containing contrast agents (preferably high concentration [>300 mg I/L]) at an injection rate of 3–5 mL/sec. Lower concentration contrast can be used if low Kv setting is applied.
Scan acquisition timing	Pancreatic parenchymal phase at 40–50 sec and portal venous phase at 65–70 sec, following the commencement of contrast injection
Image reconstruction and display	- Axial images and multiplanar reformats (in the coronal, and per institutional preference, sagittal plane) at 2- to 3-mm interval reconstruction - MIP or 3D volumetric thick section for vascular evaluation (arteries and veins)

[b] Adapted from: Al-Hawary MM, Francis IR, Chari ST, et al. Pancreatic ductal adenocarcinoma radiology reporting template: consensus statement of the Society of Abdominal Radiology and the American Pancreatic Association. Radiology 2014;270:248-260.
[c] This pancreatic template can also be used for ampullary tumors.

Note: All recommendations are category 2A unless otherwise indicated.

Version 2.2026, 02/10/2026 © 2026 National Comprehensive Cancer Network® (NCCN®), All rights reserved. NCCN Guidelines® and this illustration may not be reproduced in any form without the express written permission of NCCN.

PLEASE NOTE that use of this NCCN Content is governed by the End-User License Agreement, and you MAY NOT distribute this Content or use it with any artificial intelligence model or tool.
Printed by Galya Basol Kochav on 2/14/2026 7:41:36 AM. Copyright © 2026 National Comprehensive Cancer Network, Inc. All Rights Reserved.

PRINCIPLES OF DIAGNOSIS, IMAGING, AND STAGING

MRI Pancreatic Adenocarcinoma Protocol[c,d]

Sequences	Plane	Slice Thickness
T2-weighted single-shot fast spin echo (SSFSE)	Coronal +/- axial	<6 mm
T1-weighted in-phase and opposed-phase gradient echo (GRE)	Axial	<6 mm
T2-weighted fat-suppressed fast spin echo (FSE)	Axial	<6 mm
Diffusion-weighted imaging (DWI)	Axial	<6 mm
Pre- and dynamic post-IV contrast administration (gadolinium[e]) 3D T1-weighted fat-suppressed gradient echo (in pancreatic, portal venous, and equilibrium phases)	Axial	Thinnest possible 2–3 mm (4–6 mm if overlapping)
T2-weighted magnetic resonance cholangiopancreatography (MRCP) (preferably 3D, fast relaxation fast spin-echo sequence [FRFSE])	Coronal	<3 mm

[c] This pancreatic template can also be used for ampullary tumors.
[d] Sheridan MB, Ward J, Guthrie JA, et al. Dynamic contrast-enhanced MR imaging and dual-phase helical CT in the preoperative assessment of suspected pancreatic cancer: a comparative study with receiver operating characteristic analysis. AJR Am J Roentgenol 1999;173:583-590.
[e] Unenhanced MRI can be obtained in cases of renal failure or contraindication to gadolinium IV contrast if enhanced CT cannot be obtained due to severe iodinated contrast allergy.

Note: All recommendations are category 2A unless otherwise indicated.

Version 2.2026, 02/10/2026 © 2026 National Comprehensive Cancer Network® (NCCN®), All rights reserved. NCCN Guidelines® and this illustration may not be reproduced in any form without the express written permission of NCCN.

PLEASE NOTE that use of this NCCN Content is governed by the End-User License Agreement, and you MAY NOT distribute this Content or use it with any artificial intelligence model or tool.
Printed by Galya Basol Kochav on 2/14/2026 7:41:36 AM. Copyright © 2026 National Comprehensive Cancer Network, Inc. All Rights Reserved.

PRINCIPLES OF DIAGNOSIS, IMAGING, AND STAGING
PANCREATIC ADENOCARCINOMA RADIOLOGY REPORTING TEMPLATE[b,c]

Morphologic Evaluation			
Appearance (in the pancreatic parenchymal phase)	☐ Hypoattenuating	☐ Isoattenuating	☐ Hyperattenuating
Size (maximal axial dimension in centimeters)	☐ Measurable	☐ Nonmeasurable (isoattenuating tumors)	
Location[f]	☐ Head/uncinate (right of SMV)	☐ Neck (anterior to superior mesenteric vein [SMV]/portal vein [PV] confluence)[g]	☐ Body/tail (left of SMV)
Pancreatic duct narrowing/abrupt cutoff with or without upstream dilatation	☐ Present	☐ Absent	
Biliary tree abrupt cutoff with or without upstream dilatation	☐ Present	☐ Absent	

[b] Adapted from: Al-Hawary MM, Francis IR, Chari ST, et al. Pancreatic ductal adenocarcinoma radiology reporting template: consensus statement of the Society of Abdominal Radiology and the American Pancreatic Association. Radiology 2014;270:248-260.
[c] This pancreatic template can also be used for ampullary tumors.
[f] Location does not apply to ampullary tumors.
[g] For management of neck lesions, refer to the Principles of Surgical Technique in the NCCN Guidelines for Pancreatic Adenocarcinoma.

Note: All recommendations are category 2A unless otherwise indicated.

Version 2.2026, 02/10/2026 © 2026 National Comprehensive Cancer Network® (NCCN®), All rights reserved. NCCN Guidelines® and this illustration may not be reproduced in any form without the express written permission of NCCN.

PLEASE NOTE that use of this NCCN Content is governed by the End-User License Agreement, and you MAY NOT distribute this Content or use it with any artificial intelligence model or tool.
Printed by Galya Basol Kochav on 2/14/2026 7:41:36 AM. Copyright © 2026 National Comprehensive Cancer Network, Inc. All Rights Reserved.

PRINCIPLES OF DIAGNOSIS, IMAGING, AND STAGING
PANCREATIC ADENOCARCINOMA CANCER RADIOLOGY REPORTING TEMPLATE[b,c]

Arterial Evaluation				
Superior mesenteric artery (SMA) Contact	☐ Present	☐ Absent		
Degree of solid soft-tissue contact	☐ ≤180	☐ >180		
Degree of increased hazy attenuation/stranding contact	☐ ≤180	☐ >180		
Focal vessel narrowing or contour irregularity	☐ Present	☐ Absent		
Extension to first SMA branch	☐ Present	☐ Absent		
Celiac Axis Contact	☐ Present	☐ Absent		
Degree of solid soft-tissue contact	☐ ≤180	☐ >180		
Degree of increased hazy attenuation/stranding contact	☐ ≤180	☐ >180		
Focal vessel narrowing or contour irregularity	☐ Present	☐ Absent		
CHA Contact	☐ Present	☐ Absent		
Degree of solid soft-tissue contact	☐ ≤180	☐ >180		
Degree of increased hazy attenuation/stranding contact	☐ ≤180	☐ >180		
Focal vessel narrowing or contour irregularity	☐ Present	☐ Absent		
Extension to celiac axis	☐ Present	☐ Absent		
Extension to bifurcation of right/left hepatic artery	☐ Present	☐ Absent		
Arterial Variant	☐ Present	☐ Absent		
Variant anatomy	☐ Accessory right hepatic artery	☐ Replaced right hepatic artery	☐ Replaced common hepatic artery	☐ Others (origin of replaced or accessory artery) _____
Variant vessel contact	☐ Present	☐ Absent		
Degree of solid soft-tissue contact	☐ ≤180	☐ >180		
Degree of increased hazy attenuation/stranding contact	☐ ≤180	☐ >180		
Focal vessel narrowing or contour irregularity	☐ Present	☐ Absent		

[b] Adapted from: Al-Hawary MM, Francis IR, Chari ST, et al. Pancreatic ductal adenocarcinoma radiology reporting template: consensus statement of the Society of Abdominal Radiology and the American Pancreatic Association. Radiology 2014;270:248-260.
[c] This pancreatic template can also be used for ampullary tumors.

Note: All recommendations are category 2A unless otherwise indicated.

Version 2.2026, 02/10/2026 © 2026 National Comprehensive Cancer Network® (NCCN®), All rights reserved. NCCN Guidelines® and this illustration may not be reproduced in any form without the express written permission of NCCN.

PLEASE NOTE that use of this NCCN Content is governed by the End-User License Agreement, and you MAY NOT distribute this Content or use it with any artificial intelligence model or tool.
Printed by Galya Basol Kochav on 2/14/2026 7:41:36 AM. Copyright © 2026 National Comprehensive Cancer Network, Inc. All Rights Reserved.

PRINCIPLES OF DIAGNOSIS, IMAGING, AND STAGING
PANCREATIC ADENOCARCINOMA CANCER RADIOLOGY REPORTING TEMPLATE[b,c]

Venous Evaluation			
Main Portal Vein (MPV) Contact	☐ Present	☐ Absent	☐ Complete occlusion
Degree of solid soft-tissue contact	☐ ≤180	☐ >180	
Degree of increased hazy attenuation/stranding contact	☐ ≤180	☐ >180	
Focal vessel narrowing or contour irregularity (tethering or tear drop)	☐ Present	☐ Absent	
SMV Contact	☐ Present	☐ Absent	☐ Complete occlusion
Degree of solid soft-tissue contact	☐ ≤180	☐ >180	
Degree of increased hazy attenuation/stranding contact	☐ ≤180	☐ >180	
Focal vessel narrowing or contour irregularity (tethering or tear drop)	☐ Present	☐ Absent	
Extension	☐ Present	☐ Absent	
Other			
Thrombus within vein (tumor, bland)	☐ Present ☐ MPV ☐ SMV ☐ Splenic vein	☐ Absent	
Venous collaterals	☐ Present ☐ Around pancreatic head ☐ Porta hepatis ☐ Root of the mesentery ☐ Left upper quadrant	☐ Absent	

[b] Adapted from: Al-Hawary MM, Francis IR, Chari ST, et al. Pancreatic ductal adenocarcinoma radiology reporting template: consensus statement of the Society of Abdominal Radiology and the American Pancreatic Association. Radiology 2014;270:248-260.
[c] This pancreatic template can also be used for ampullary tumors.

Note: All recommendations are category 2A unless otherwise indicated.

Version 2.2026, 02/10/2026 © 2026 National Comprehensive Cancer Network® (NCCN®), All rights reserved. NCCN Guidelines® and this illustration may not be reproduced in any form without the express written permission of NCCN.

PLEASE NOTE that use of this NCCN Content is governed by the End-User License Agreement, and you MAY NOT distribute this Content or use it with any artificial intelligence model or tool.
Printed by Galya Basol Kochav on 2/14/2026 7:41:36 AM. Copyright © 2026 National Comprehensive Cancer Network, Inc. All Rights Reserved.

PRINCIPLES OF DIAGNOSIS, IMAGING, AND STAGING
PANCREATIC ADENOCARCINOMA CANCER RADIOLOGY REPORTING TEMPLATE[b,c]

Extrapancreatic Evaluation		
Liver lesions	☐ Present ☐ Suspicious ☐ Indeterminate ☐ Likely benign	☐ Absent
Peritoneal or omental nodules	☐ Present	☐ Absent
Ascites	☐ Present	☐ Absent
Suspicious lymph nodes	☐ Present ☐ Porta hepatis ☐ Celiac ☐ Splenic hilum ☐ Paraaortic ☐ Aortocaval ☐ Other_____	☐ Absent
Other extrapancreatic disease (invasion of adjacent structures)	☐ Present • Organs involved: _____	☐ Absent
Impression		
	Tumor size: _____	Tumor location: _____
Vascular contact	☐ Present • Vessel involved: _____ • Extent: _____	☐ Absent
Metastasis	☐ Present (Location _____)	☐ Absent

[b] Adapted from: Al-Hawary MM, Francis IR, Chari ST, et al. Pancreatic ductal adenocarcinoma radiology reporting template: consensus statement of the Society of Abdominal Radiology and the American Pancreatic Association. Radiology 2014;270:248-260.
[c] This pancreatic template can also be used for ampullary tumors.

Note: All recommendations are category 2A unless otherwise indicated.

Version 2.2026, 02/10/2026 © 2026 National Comprehensive Cancer Network® (NCCN®), All rights reserved. NCCN Guidelines® and this illustration may not be reproduced in any form without the express written permission of NCCN.

PLEASE NOTE that use of this NCCN Content is governed by the End-User License Agreement, and you MAY NOT distribute this Content or use it with any artificial intelligence model or tool.
Printed by Galya Basol Kochav on 2/14/2026 7:41:36 AM. Copyright © 2026 National Comprehensive Cancer Network, Inc. All Rights Reserved.

PRINCIPLES OF STENT MANAGEMENT

- Stent placement is not routinely recommended prior to planned surgery; however, a stent may be considered for symptoms of cholangitis/fever or severe symptomatic jaundice (intense pruritus), or if surgery is being delayed for any reason, including neoadjuvant therapy.
- ERCP-guided biliary drainage is preferred. If ERCP is not possible, a PTC approach may be used.
- Stents should be as short as feasible.
- Self-expanding metal stents (SEMS) should only be placed if tissue diagnosis is confirmed.
- For neoadjuvant therapy, fully covered SEMS are preferred since they can be removed/exchanged.

Note: All recommendations are category 2A unless otherwise indicated.

Version 2.2026, 02/10/2026 © 2026 National Comprehensive Cancer Network® (NCCN®), All rights reserved. NCCN Guidelines® and this illustration may not be reproduced in any form without the express written permission of NCCN.

PLEASE NOTE that use of this NCCN Content is governed by the End-User License Agreement, and you MAY NOT distribute this Content or use it with any artificial intelligence model or tool.
Printed by Galya Basol Kochav on 2/14/2026 7:41:36 AM. Copyright © 2026 National Comprehensive Cancer Network, Inc. All Rights Reserved.

PRINCIPLES OF SURGICAL TECHNIQUE

Ampullary adenomas without suspicion of adenocarcinoma may be safely removed endoscopically, including those with high-grade dysplasia. Local extent of the lesion may be assessed with endoscopy with image enhancement, and with EUS and MRI/MRCP for intraductal and submucosal invasion. EUS may be considered in all lesions, which may be endoscopically removed, to assess intraductal or parenchymal invasion. If deep invasion is suspected, EUS with biopsies may be pursued at that time. Endoscopic removal of ampullary adenomas should be performed at a high-volume center.[1-3]

The goals of pancreatoduodenectomy for adenocarcinoma of the ampulla of Vater include an oncologic resection of the primary tumor and regional lymph nodes. Careful intraoperative staging should rule out peritoneal, liver, and distant lymph node metastases, and resection of the primary tumor should only be done in the absence of distant disease. Surgery should be done efficiently, minimizing blood loss, operative time, and cost. Management of a soft pancreatic remnant should be anticipated.

Pancreatoduodenectomy (Whipple technique)

The goals of surgical extirpation of carcinoma of the ampulla of Vater focus on the achievement of an R0 resection, as a margin-positive specimen is associated with poor long-term survival.[4,5] Achievement of a margin-negative dissection must focus on meticulous perivascular dissection of the lesion similar to pancreatic cancer, recognition of the need for vascular resection and/or reconstruction, and the potential need for extra-pancreatic organ resection. Medial dissection of pancreatic head lesions is best achieved by complete mobilization of the PV and SMV from the uncinate process (assuming no evidence of tumor infiltration). Skeletalization of the lateral, posterior, and anterior borders of the SMA down to the level of the adventitia will maximize uncinate yield and radial margin.[6,7]

- The need for lateral venorrhaphy or complete portal or SMV resection and reconstruction to achieve an R0 resection may be suggested but is often not known until division of the pancreatic neck has occurred. Tethering of the carcinoma to the lateral wall of the PV while uncommon, requires careful dissection to free the vein from the pancreatic head if it is possible to do so. Differentiation of tumor infiltration into the vein wall from tumor-related desmoplasia is frequently impossible to ascertain. Data support an aggressive approach to partial or complete vein excision if tumor infiltration is suspected.

Consider frozen section analysis of the pancreatic neck and bile duct. To avoid cautery artifact that may confound the frozen section, assess the pancreatic neck and bile duct at time of surgery by frozen section approximately 5 mm from the transection margin. If tumor is located within 5 mm of margins, consider further excision of the pancreas and bile duct to ensure at least 5 mm of clearance.

References

Note: All recommendations are category 2A unless otherwise indicated.

Version 2.2026, 02/10/2026 © 2026 National Comprehensive Cancer Network® (NCCN®), All rights reserved. NCCN Guidelines® and this illustration may not be reproduced in any form without the express written permission of NCCN.

PLEASE NOTE that use of this NCCN Content is governed by the End-User License Agreement, and you MAY NOT distribute this Content or use it with any artificial intelligence model or tool.
Printed by Galya Basol Kochav on 2/14/2026 7:41:36 AM. Copyright © 2026 National Comprehensive Cancer Network, Inc. All Rights Reserved.

PRINCIPLES OF SURGICAL TECHNIQUE
REFERENCES

1 Bassan M, Bourke M. Endoscopic ampullectomy: a practical guide. J Interv Gastroenterol 2012;2:23-30.
2 Alvarez-Sánchez MV, Napoleon B. EUS and ampullary adenoma: Why? When?. Endosc Int Open 2016;4:E1319-E1321.
3 Patel V, Jowell P, Obando J, et al. Does ampullary adenoma size predict invasion on EUS? Does invasion on EUS predict presence of malignancy? Endosc Int Open 2016;4:E1313-E1318.
4 Bilimoria KY, Talamonti MS, Sener SF, et al. Effect of hospital volume on margin status after pancreaticoduodenectomy for cancer. J Am Coll Surg 2008;207:510-519.
5 Winter JM, Cameron JL, Campbell KA, et al. 1423 pancreaticoduodenectomies for pancreatic cancer: A single-institution experience. J Gastrointest Surg 2006;10:1199-1210; discussion 1210-1191.
6 Yeo TP, Hruban RH, Leach SD, et al. Pancreatic cancer. Curr Probl Cancer 2002;26:176-275.
7 Nakeeb A, Lillemoe KD, Grosfeld JL. Surgical techniques for pancreatic cancer. Minerva Chir 2004;59:151-163.

Note: All recommendations are category 2A unless otherwise indicated.

Version 2.2026, 02/10/2026 © 2026 National Comprehensive Cancer Network® (NCCN®), All rights reserved. NCCN Guidelines® and this illustration may not be reproduced in any form without the express written permission of NCCN.

PLEASE NOTE that use of this NCCN Content is governed by the End-User License Agreement, and you MAY NOT distribute this Content or use it with any artificial intelligence model or tool.
Printed by Galya Basol Kochav on 2/14/2026 7:41:36 AM. Copyright © 2026 National Comprehensive Cancer Network, Inc. All Rights Reserved.

PATHOLOGIC ANALYSIS: SPECIMEN ORIENTATION, HISTOLOGIC SECTIONS, AND REPORTING

The primary purpose of pathologic analysis of the ampullary specimen is to determine the pathologic stage of the tumor, completeness of resection, and other histopathologic features that impact prognosis and clinical management.

Ampullectomy Specimen

- Specimen orientation: Specimen orientation and inking involve both the pathologist and surgeon/endoscopist, as this will help to ensure accurate assessment of the size and extent of the tumor. There should be either direct communication between the surgeon/endoscopist and pathologist for proper orientation and margin identification, or the surgeon/endoscopist should identify the important margins with a clearly understood and documented method (eg, written on the pathology requisition); for example: the deep (radial), duodenal mucosal, and any other relevant margins should be marked.

Pancreatoduodenectomy

- Specimen orientation: Specimen orientation and inking involve both the pathologist and surgeon, as this will help to ensure accurate assessment of the size and extent of the tumor. There should be either direct communication between the surgeon and pathologist for proper orientation and margin identification, or the surgeon should identify the important margins with a clearly understood and documented method (eg, written on the pathology requisition, such as the bile duct margin and, if present, the proximal and distal margins of the portal vein should be marked).
- Every effort should be made to identify all regional lymph nodes within the pancreatoduodenectomy specimen. Adequate lymph node assessment may be more challenging after neoadjuvant therapy, but the Panel consensus is an assessment of at least 12 lymph nodes.[1-3]

References

Note: All recommendations are category 2A unless otherwise indicated.

Version 2.2026, 02/10/2026 © 2026 National Comprehensive Cancer Network® (NCCN®), All rights reserved. NCCN Guidelines® and this illustration may not be reproduced in any form without the express written permission of NCCN.

PLEASE NOTE that use of this NCCN Content is governed by the End-User License Agreement, and you MAY NOT distribute this Content or use it with any artificial intelligence model or tool.
Printed by Galya Basol Kochav on 2/14/2026 7:41:36 AM. Copyright © 2026 National Comprehensive Cancer Network, Inc. All Rights Reserved.

PATHOLOGIC ANALYSIS: SPECIMEN ORIENTATION, HISTOLOGIC SECTIONS, AND REPORTING

Pancreatoduodenectomy (continued)

- Margins
  - Definitions of the margins and uniformity of nomenclature are critical to accurate reporting.
    - ◊ SMA (retroperitoneal/uncinate) Margin: The most important margin is the soft tissue directly adjacent to the proximal 3 to 4 cm of the SMA.[4] This margin is often referred to as the "retroperitoneal margin" or "posterior margin," but has also been referred to as the "uncinate margin" or "mesenteric margin." More recently, this margin has been referred to as the "SMA margin" to correlate with its location on the specimen. Radial, rather than en face, sections of this margin will more clearly demonstrate how closely this margin is approached by tumor. Therefore, the margin tissue should be inked, shaved/amputated, and then sectioned perpendicular to the ink and submitted entirely for histologic examination.
    - ◊ PV Margins: If an en bloc partial or complete vein resection is added to the surgical specimen, it should be marked separately. En face proximal and distal end margins of the vein should be separately submitted as "Proximal Portal Vein Margin" and "Distal Portal Vein Margin." A section documenting tumor invasion into the vein wall should also be submitted.
    - ◊ Pancreatic Neck (transection) Margin: This is the en face section of the transected pancreatic neck. Care should be taken when placing the section into the cassette to document the orientation of the section with respect to the true margin (eg, facing down so that the initial section into the block represents the true margin, or facing up so that the initial section represents the surface opposite the true margin).
    - ◊ Bile Duct Margin: This is the en face section of the bile duct end. The section should be removed from the unopened duct and care should be taken when placing the section into the cassette to document the orientation of the section with respect to the true margin (eg, facing down so that the initial section into the block represents the true margin, or facing up so that the initial section represents the surface opposite the true margin).
  - Other margins analyzed in pancreatoduodenectomy specimens include the proximal (gastric or enteric) and distal enteric margins (en face sections).
  - Collectively, these margins and pancreatic tissue surfaces constitute the circumferential surface of the specimen. Designating the various specific margins and surfaces with different colored inks will allow recognition on microscopy.

References

Note: All recommendations are category 2A unless otherwise indicated.

Version 2.2026, 02/10/2026 © 2026 National Comprehensive Cancer Network® (NCCN®), All rights reserved. NCCN Guidelines® and this illustration may not be reproduced in any form without the express written permission of NCCN.

PLEASE NOTE that use of this NCCN Content is governed by the End-User License Agreement, and you MAY NOT distribute this Content or use it with any artificial intelligence model or tool.
Printed by Galya Basol Kochav on 2/14/2026 7:41:36 AM. Copyright © 2026 National Comprehensive Cancer Network, Inc. All Rights Reserved.

PATHOLOGIC ANALYSIS: SPECIMEN ORIENTATION, HISTOLOGIC SECTIONS, AND REPORTING

Pancreatoduodenectomy (continued)

- Other Circumferential Surfaces
  - Posterior (non-SMA margin) Surface: This surface consists of the posterior caudad aspect of the pancreatic head that is not part of the SMA margin and that appears to be covered by loose connective tissue. This surface is not a true margin, but identification and reporting of this surface when positive is recommended, but not currently required, for data collection purposes, so that the association with risk of recurrence and other prognostic indicators can be studied. Radial, rather than en face, sections of this surface will more clearly demonstrate whether it is involved by tumor. In some instances, this surface may already be included in sections of the SMA margin.
  - SMV Groove: Also referred to as the vascular groove/vascular bed surface, this is the smooth-surfaced groove on the posterior-medial surface of the pancreatic head that rests over the SMV. This surface is not a true margin, but identification and reporting of this surface when positive is recommended, but not currently required, for data collection purposes, so that the association with risk of recurrence and other prognostic indicators can be studied. Radial, rather than en face, sections of this surface will more clearly demonstrate whether it is involved by tumor, and also will provide the distance of the tumor from the surface. As is true for the posterior (non-SMA margin) surface, in some instances, this surface may be included in the same sections as the SMA margin.
  - Anterior Surface: The anterior surface is not a true margin, but identification and reporting of this surface when positive is recommended, but not currently required, for data collection purposes, so that the association with risk of recurrence and other prognostic indicators can be studied. In some cases where the anterior surface is adherent to other structures, from which it is surgically dissected or transected, it should be considered an additional circumferential margin, for which the closest distance from the tumor should be reported.
- Histologic Sectioning
  - The approach to histologic sectioning is determined by the unique characteristics of the tumor, but is also influenced by institutional preferences, expertise, and experience. For the examination of ampullary carcinoma, it is recommended that the pancreas be bivalved along probes placed in the bile and pancreatic ducts. Each half should then be sectioned perpendicularly to the inked anterior and posterior surfaces, and sections should be submitted in a manner that allows for accurate assessment of the extent of invasion into the sphincter of Oddi, duodenal wall, and pancreas. This approach also helps determine the relationship between invasive carcinoma and any associated precursor lesions, as well as its relationship to the pancreatic circumferential tissue margins mentioned above.
  - Per the current College of American Pathologists (CAP) protocol, the presence of tumor at or within 1 mm of resection margin constitutes a positive margin, although this recommendation is based primarily on extrapolation of data on rectal adenocarcinoma. There is currently a lack of definitive evidence for what constitutes an adequate margin in ampullary carcinoma resection specimens.
  - Tumor clearance should be reported with millimeter accuracy for all margins where tumor is close (within ≤1.0 cm of the tumor). This may be done using either mm (eg, 2 mm) or cm (eg, 0.2 cm). For margins distant from tumor (>1.0 cm from tumor), tumor clearance may be reported with centimeter accuracy.
  - Attached organs resected with the specimen en bloc require serial sectioning to assess not only direct extension, but metastatic deposits as well. One section that demonstrates direct invasion of the organ and/or a separate metastatic deposit is required.

References

Note: All recommendations are category 2A unless otherwise indicated.

Version 2.2026, 02/10/2026 © 2026 National Comprehensive Cancer Network® (NCCN®), All rights reserved. NCCN Guidelines® and this illustration may not be reproduced in any form without the express written permission of NCCN.

PLEASE NOTE that use of this NCCN Content is governed by the End-User License Agreement, and you MAY NOT distribute this Content or use it with any artificial intelligence model or tool.
Printed by Galya Basol Kochav on 2/14/2026 7:41:36 AM. Copyright © 2026 National Comprehensive Cancer Network, Inc. All Rights Reserved.

PATHOLOGIC ANALYSIS: SPECIMEN ORIENTATION, HISTOLOGIC SECTIONS, AND REPORTING

Histologic Subtyping

- The NCCN Panel recommends histologic subtyping.
- Report the histologic subtype as intestinal, pancreatobiliary, or mixed.[5-10]
  - Intestinal-type tumors are characterized by the presence of large tubules lined by tall columnar cells with elongated, pseudostratified, hyperchromatic nuclei resembling colonic-type adenocarcinoma.[5] They may also exhibit an immunophenotypic staining profile similar to that of colonic-type adenocarcinomas (typically positive for CK20, CDX2, or MUC2 with negative MUC1, or positive for CK20, CDX2, and MUC2, irrespective of MUC1 staining).[8-10]
  - Pancreatobiliary-type tumors are characterized by variably differentiated glands lined by non-stratified cuboidal or low columnar eosinophilic epithelium exhibiting round to oval, irregular, hypochromatic, or hyperchromatic nuclei with vesicular chromatin and irregular nuclear contours and a high nuclear to cytoplasmic ratio. Abundant desmoplastic stroma may be present. They may exhibit an immunophenotypic staining profile (positive for MUC1 and negative for CDX2 and MUC2, irrespective of CK20 staining) similar to that of pancreatic/biliary carcinomas.[8-10] It should be noted that a significant proportion of ampullary adenocarcinomas may be of mixed or ambiguous phenotype.[5,8,9] These ambiguous cases should be classified as tubular adenocarcinoma with mixed features,[9] but we recommend that the predominant pattern be noted in the pathology report for data collection purposes and future analysis.
- Current data on the independent prognostic and predictive value of subtyping with regard to adjuvant therapy outcomes are conflicting, with some studies suggesting no significant independent association between histologic subtype and adjuvant therapy response or overall or disease-free survival (DFS).[11-16]
- Although immunohistochemistry may be helpful in aiding the determination of histologic subtype, it is not required, as there may be overlap in the immunohistochemical profiles of intestinal and pancreatobiliary-type adenocarcinomas,[8,17,18] which may make current immunohistochemical panels unreliable for definitive determination of subtype.[5,19]

References

Note: All recommendations are category 2A unless otherwise indicated.

Version 2.2026, 02/10/2026 © 2026 National Comprehensive Cancer Network® (NCCN®), All rights reserved. NCCN Guidelines® and this illustration may not be reproduced in any form without the express written permission of NCCN.

PLEASE NOTE that use of this NCCN Content is governed by the End-User License Agreement, and you MAY NOT distribute this Content or use it with any artificial intelligence model or tool.
Printed by Galya Basol Kochav on 2/14/2026 7:41:36 AM. Copyright © 2026 National Comprehensive Cancer Network, Inc. All Rights Reserved.

PATHOLOGIC ANALYSIS: SPECIMEN ORIENTATION, HISTOLOGIC SECTIONS, AND REPORTING

- The NCCN Ampullary Adenocarcinoma Panel currently supports pathology synoptic reports from the CAP. The proposal included herein is an abbreviated minimum analysis of ampullary adenocarcinoma specimens from the CAP recommendations. For more information about pathologic analysis, please refer to the CAP Cancer Protocol Template for carcinoma of the Ampulla of Vater.[20] In addition to the standard tumor node metastasis (TNM) staging, other variables are included, all of which have established or emerging prognostic implications in the evolution of this disease.[7,8]
- Treatment effect should be assessed and reported by the pathologist, as tumor viability may impact postoperative therapy options.[11,21]

Specimen Type

- Tumor size (obtained from careful gross measurement of the largest dimension of the tumor in centimeters, and corroborated on microscopic examination)
- Histologic type (H) and subtype (intestinal, pancreatobiliary, or mixed)
- Histologic grade [G (x–3)]
- Primary tumor stage [T (x–4)]
- Regional lymph nodes [N (x–2)][a]
  - # nodes recovered
  - # nodes involved
- Metastases [M (0–1)]
- Margins and other circumferential surfaces: Involvement should be defined and surgical clearance measured with millimeter accuracy for close (within 1.0 cm of tumor) margin
  - Pancreatoduodenectomy specimen:
    - SMA (retroperitoneal/uncinate) margin
    - Posterior surface
    - SMV groove
    - Pancreatic neck (transection) margin
    - Bile duct margin
    - Gastric/enteric margins
    - Anterior surface
  - Ampullectomy specimen:
    - Bile duct margin
    - Pancreatic duct margin
    - Duodenal mucosal margin
    - Deep (radial) margin
- Lymphovascular invasion (L)
- Additional pathologic findings
  - Dysplasia/adenoma (including intra-ampullary papillary tubular neoplasm [IAPN] or peri-ampullary duodenal adenoma)
- Tumor regression score following prior chemotherapy and/or RT

Final stage: T, N, M (per AJCC)

[a] Every effort should be made to identify all regional lymph nodes within the ampullary specimen (Discussion).

References

Note: All recommendations are category 2A unless otherwise indicated.

Version 2.2026, 02/10/2026 © 2026 National Comprehensive Cancer Network® (NCCN®), All rights reserved. NCCN Guidelines® and this illustration may not be reproduced in any form without the express written permission of NCCN.

PLEASE NOTE that use of this NCCN Content is governed by the End-User License Agreement, and you MAY NOT distribute this Content or use it with any artificial intelligence model or tool.
Printed by Galya Basol Kochav on 2/14/2026 7:41:36 AM. Copyright © 2026 National Comprehensive Cancer Network, Inc. All Rights Reserved.

PATHOLOGIC ANALYSIS: SPECIMEN ORIENTATION, HISTOLOGIC SECTIONS, AND REPORTING
REFERENCES

[1] Partelli S, Crippa S, Capelli P, et al. Adequacy of lymph node retrieval for ampullary cancer and its association with improved staging and survival. World J Surg 2013;37:1397-1404.
[2] Balci S, Basturk O, Saka B, et al. Substaging nodal status in ampullary carcinomas has significant prognostic value: proposed revised staging based on an analysis of 313 well-characterized cases. Ann Surg Oncol 2015;22:4392-4401.
[3] Nassour I, Christie A, Choti MA, et al. Determining the adequate examined lymph node count in resected ampullary adenocarcinoma-A national cohort study. J Gastrointest Surg 2018;22:792-801.
[4] Todoroki T, Koike N, Morishita Y, et al. Patterns and predictors of failure after curative resections of carcinoma of the ampulla of Vater. Ann Surg Oncol 2003;10:1176-1183.
[5] Reid MD, Balci S, Ohike N, et al. Ampullary carcinoma is often of mixed or hybrid histologic type: an analysis of reproducibility and clinical relevance of classification as pancreatobiliary versus intestinal in 232 cases. Mod Pathol 2016;29:1575-1585.
[6] Westgaard A, Tafjord S, Farstad IN, et al. Pancreatobiliary versus intestinal histologic type of differentiation is an independent prognostic factor in resected periampullary adenocarcinoma. BMC Cancer 2008;8:170.
[7] Kumari N, Prabha K, Singh RK, et al. Intestinal and pancreatobiliary differentiation in periampullary carcinoma: the role of immunohistochemistry. Hum Pathol 2013;44:2213-2219.
[8] Ang DC, Shia J, Tang LH, et al. The utility of immunohistochemistry in subtyping adenocarcinoma of the ampulla of vater. Am J Surg Pathol 2014;38:1371-1379.
[9] Chang DK, Jamieson NB, Johns AL. Histomolecular phenotypes and outcome in adenocarcinoma of the ampulla of vater. J Clin Oncol 2013;31:1348-1356.
[10] Schueneman A, Goggins M, Ensor J, et al. Validation of histomolecular classification utilizing histological subtype, MUC1, and CDX2 for prognostication of resected ampullary adenocarcinoma. Br J Cancer 2015;113:64-68.
[11] Yamashita S, Overman MJ, Wang H, et al. Pathologic response to preoperative therapy as a novel prognosticator for ampullary and duodenal adenocarcinoma. Ann Surg Oncol 2017;24:3954-3963.
[12] Neoptolemos JP, Stocken DD, Friess H, et al. A randomized trial of chemoradiotherapy and chemotherapy after resection of pancreatic cancer. N Engl J Med 2004;350:1200-1210. Erratum in: N Engl J Med 2004;351:726.
[13] Neoptolemos JP, Moore MJ, Cox TF, et al. Effect of adjuvant chemotherapy with fluorouracil plus folinic acid or gemcitabine vs observation on survival in patients with resected periampullary adenocarcinoma: The ESPAC-3 Periampullary Cancer Randomized Trial. JAMA 2012;308:147-156.
[14] Jin Z, Hartgers ML, Sanhueza CT, et al. Prognostic factors and benefits of adjuvant therapy after pancreatoduodenectomy for ampullary adenocarcinoma: Mayo Clinic experience. Eur J Surg Oncol 2018;44:677-683.
[15] Ecker BL, Vollmer CM Jr, Behrman SW, et al. Role of adjuvant multimodality therapy after curative-intent resection of ampullary carcinoma. JAMA Surg 2019;154:706-714.
[16] Moekotte AL, Lof S, Van Roessel S, et al. Histopathologic predictors of survival and recurrence in resected ampullary adenocarcinoma. Ann Surg 2020;272:1086-1093.
[17] Chu PG, Schwarz RE, Lau SK et al. Immunohistochemical staining in the diagnosis of pancreatobiliary and ampulla of Vater adenocarcinoma: application of CDX2, CK17, MUC1, and MUC2. Am J Surg Pathol 2005;29:359-367.
[18] Werling RW, Yaziji H, Bacchi CE, et al. CDX2, a highly sensitive and specific marker of adenocarcinomas of intestinal origin: an immunohistochemical survey of 476 primary and metastatic carcinomas. Am J Surg Pathol 2003;27:303-310.
[19] Xue Y, Reid MD, Balci S, et al. Immunohistochemical classification of ampullary carcinomas: Critical reappraisal fails to confirm prognostic relevance for recently proposed panels, and Highlights MUC5AC as a strong prognosticator. Am J Surg Pathol 2017;41:865-876.
[20] Burgart LJ, Shi C, Adsay VN, et al. Protocol for the Examination of Specimens from Patients with Carcinoma of the Ampulla of Vater. College of American Pathologists. Cancer Protocol Templates; 2021. Available at: https://documents.cap.org/protocols/Ampulla_4.2.0.0.REL_CAPCP.pdf.
[21] Palta M, Patel P, Broadwater G, et al. Carcinoma of the ampulla of Vater: patterns of failure following resection and benefit of chemoradiotherapy. Ann Surg Oncol 2012;19:1535-1540.

Note: All recommendations are category 2A unless otherwise indicated.

Version 2.2026, 02/10/2026 © 2026 National Comprehensive Cancer Network® (NCCN®), All rights reserved. NCCN Guidelines® and this illustration may not be reproduced in any form without the express written permission of NCCN.

PLEASE NOTE that use of this NCCN Content is governed by the End-User License Agreement, and you MAY NOT distribute this Content or use it with any artificial intelligence model or tool.
Printed by Galya Basol Kochav on 2/14/2026 7:41:36 AM. Copyright © 2026 National Comprehensive Cancer Network, Inc. All Rights Reserved.

PRINCIPLES OF SYSTEMIC THERAPY

Neoadjuvant Therapy (AMP-E 1 of 11)

Adjuvant Therapy (AMP-E 2 of 11)

Metastatic Disease (First-Line Therapy) (AMP-E 3 of 11)

Therapy for Disease Progression (AMP-E 5 of 11)

Chemoradiation (AMP-E 8 of 11)

General Principles:

- Systemic therapy is used in all stages of ampullary cancer. This could include neoadjuvant and adjuvant therapy for localized, potentially resectable disease, and first-line or subsequent therapy for locally advanced, metastatic, and recurrent disease.
- Systemic therapy type may depend on the histologic subtype of ampullary cancer: intestinal versus pancreatobiliary or mixed.
- For full systemic therapy options for intestinal type ampullary cancer, please review the NCCN Guidelines for Colon Cancer as related to adjuvant systemic therapy and therapy for metastatic disease. Where neoadjuvant chemotherapy is recommended, the same regimens for advanced/metastatic disease may be used.
- For full systemic therapy options for pancreatobiliary type and mixed histology type ampullary cancer, please review the NCCN Guidelines for Hepatocellular Carcinoma, NCCN Guidelines for Biliary Tract Cancers, and NCCN Guidelines for Pancreatic Adenocarcinoma, as related to adjuvant systemic therapy and therapy for metastatic disease. Where neoadjuvant chemotherapy is recommended, the same regimens used for advanced/metastatic disease may be used.
- Goals of systemic therapy should be discussed with patients prior to initiation of therapy, and enrollment in a clinical trial is strongly encouraged.
- Close follow-up of patients undergoing chemotherapy is indicated.
- For regimens where RT or chemoradiation is included, see Principles of Radiation Therapy (AMP-F) for more details related to radiation delivery, including recommended technique and dose.
- To optimize the care of older adults, see the NCCN Guidelines for Older Adult Oncology.
- An FDA-approved biosimilar is an appropriate substitute for any recommended systemic biologic therapy in the NCCN Guidelines.
- For information regarding DPYD testing, see the NCCN Guidelines for Colon Cancer.
- Nivolumab and hyaluronidase-nvhy is not approved for concurrent use with IV ipilimumab; however, for nivolumab monotherapy, nivolumab and hyaluronidase-nvhy subcutaneous injection may be substituted for IV nivolumab. Nivolumab and hyaluronidase-nvhy has different dosing and administration instructions compared to IV nivolumab.
- Pembrolizumab and berahyaluronidase alfa-pmph subcutaneous injection may be substituted for IV pembrolizumab. Pembrolizumab and berahyaluronidase alfa-pmph has different dosing and administration instructions compared to IV pembrolizumab.

Note: All recommendations are category 2A unless otherwise indicated.

Version 2.2026, 02/10/2026 © 2026 National Comprehensive Cancer Network® (NCCN®), All rights reserved. NCCN Guidelines® and this illustration may not be reproduced in any form without the express written permission of NCCN.

PLEASE NOTE that use of this NCCN Content is governed by the End-User License Agreement, and you MAY NOT distribute this Content or use it with any artificial intelligence model or tool.
Printed by Galya Basol Kochav on 2/14/2026 7:41:36 AM. Copyright © 2026 National Comprehensive Cancer Network, Inc. All Rights Reserved.

PRINCIPLES OF SYSTEMIC THERAPY

Neoadjuvant Therapy (Localized Disease)	
• There is limited evidence to recommend neoadjuvant regimens for ampullary cancers, and most localized ampullary cancers are treated with surgery first.[1] • If recommended, neoadjuvant regimens vary with regard to the use of chemotherapy and/or radiation. When considering neoadjuvant therapy, consultation at a high-volume center is preferred. Participation in a clinical trial, if available, is encouraged.	
Pancreatobiliary and Mixed Type	**Intestinal Type**
• Albumin-bound Paclitaxel/Gemcitabine[a] • Albumin-bound Paclitaxel/Gemcitabine with subsequent chemoradiation[a,b,c] • Capecitabine/Gemcitabine • Capecitabine/Gemcitabine with subsequent chemoradiation[b,c] • Cisplatin/Gemcitabine • Cisplatin/Gemcitabine with subsequent chemoradiation[b,c] • FOLFIRINOX (Leucovorin/Fluorouracil/Irinotecan/Oxaliplatin)[d,2] or modified FOLFIRINOX[d,e] • FOLFIRINOX[d,2] or modified FOLFIRINOX[d,e] with subsequent chemoradiation[b,c]	• CAPEOX (Capecitabine/Oxaliplatin) • CAPEOX with subsequent chemoradiation[b,c] • FOLFIRINOX[d] • FOLFIRINOX[d] with subsequent chemoradiation[b,c] • FOLFOX (Leucovorin/Fluorouracil/Oxaliplatin)[3] • FOLFOX[3] with subsequent chemoradiation[b,c]

[a] Albumin-bound paclitaxel/gemcitabine is reasonable for patients with ECOG 0–2.
[b] Chemoradiation (AMP-E 8 of 11).
[c] If considering chemoradiation due to positive margins, chemotherapy should be given prior to the administration of chemoradiation.
[d] FOLFIRINOX or modified FOLFIRINOX should be limited to those with ECOG 0–1.
[e] Due to the high toxicity of this regimen, bolus fluorouracil is often omitted.

Note: All recommendations are category 2A unless otherwise indicated.

References

Version 2.2026, 02/10/2026 © 2026 National Comprehensive Cancer Network® (NCCN®), All rights reserved. NCCN Guidelines® and this illustration may not be reproduced in any form without the express written permission of NCCN.

PLEASE NOTE that use of this NCCN Content is governed by the End-User License Agreement, and you MAY NOT distribute this Content or use it with any artificial intelligence model or tool.
Printed by Galya Basol Kochav on 2/14/2026 7:41:36 AM. Copyright © 2026 National Comprehensive Cancer Network, Inc. All Rights Reserved.

PRINCIPLES OF SYSTEMIC THERAPY

Adjuvant Therapy[f,4]	
• The ESPAC-3 trial demonstrated significant improvements in DFS and overall survival (OS) with use of postoperative gemcitabine or fluorouracil as adjuvant chemotherapy versus observation in resectable ampullary adenocarcinoma.[5] • ESPAC-3 study results showed no significant difference in OS between fluorouracil/leucovorin versus gemcitabine following surgery. When the groups receiving adjuvant fluorouracil/leucovorin and adjuvant gemcitabine were compared, median survival was 23.0 months and 23.6 months, respectively.[5] • All chemotherapy regimens, with the exception of gemcitabine and fluorouracil/leucovorin, which were studied in the phase 3 ESPAC-3 clinical trial, are based on retrospective or institutional prospective studies, or are based on the NCCN Guidelines for Pancreatic Adenocarcinoma and NCCN Guidelines for Colon Cancer. • For patients who received prior neoadjuvant therapy, the adjuvant therapy options are dependent on the response to neoadjuvant therapy and other clinical considerations.	
Pancreatobiliary and Mixed Type	**Intestinal Type**
• Fluorouracil/Leucovorin (category 1)[5] • Gemcitabine (category 1)[5,6] • Capecitabine[7] • Capecitabine/Gemcitabine[8] • Cisplatin/Gemcitabine[9] • FOLFOX[10] or CAPEOX[11] • Modified FOLFIRINOX[e,g,12]	• Fluorouracil/Leucovorin (category 1)[5] • Capecitabine[13] • FOLFOX[10] or CAPEOX[11,14]

[e] Due to the high toxicity of this regimen, bolus fluorouracil is often omitted.
[f] For stage II and stage III resected disease, chemotherapy may be followed by chemoradiation.
[g] Modified FOLFIRINOX should be limited to those with ECOG 0–1.

Note: All recommendations are category 2A unless otherwise indicated.

References

Version 2.2026, 02/10/2026 © 2026 National Comprehensive Cancer Network® (NCCN®), All rights reserved. NCCN Guidelines® and this illustration may not be reproduced in any form without the express written permission of NCCN.

PLEASE NOTE that use of this NCCN Content is governed by the End-User License Agreement, and you MAY NOT distribute this Content or use it with any artificial intelligence model or tool.
Printed by Galya Basol Kochav on 2/14/2026 7:41:36 AM. Copyright © 2026 National Comprehensive Cancer Network, Inc. All Rights Reserved.

PRINCIPLES OF SYSTEMIC THERAPY

Metastatic Disease (First-Line Therapy)[h]			
	Pancreatobiliary/Mixed Type	**Intestinal Type**	**Targeted Systemic Therapies**
Good PS 0-1	• Albumin-bound Paclitaxel/ Gemcitabine[15] • Capecitabine/Gemcitabine[16] • Cisplatin/Gemcitabine[9] • Cisplatin/Gemcitabine + Durvalumab[j,17] • FOLFIRINOX[18] or modified FOLFIRINOX[e,19] • FOLFOX • NALIRIFOX (Liposomal Irinotecan/ Fluorouracil/Leucovorin/Oxaliplatin)[k,20]	• CAPEOX[11] • CAPEOX + Bevacizumab[21,22] • FOLFIRI (Leucovorin/Fluorouracil/ Irinotecan)[23] • FOLFIRI + Bevacizumab • FOLFIRINOX[e,18,24] • FOLFIRINOX + Bevacizumab • FOLFOX[25] • FOLFOX + Bevacizumab[22,26]	Useful in Certain Circumstances: • Entrectinib or Larotrectinib or Repotrectinib (if *NTRK* gene fusion-positive)[29,30,31,32] • Ipilimumab + Nivolumab (if MSI-H or dMMR, for intestinal type only)[j,33] • Pembrolizumab (if MSI-H, dMMR, or TMB-H [≥10 mut/Mb])[j,34,35] • Selpercatinib (if *RET* gene fusion-positive) • Dabrafenib/Trametinib (if *BRAF* V600E mutation-positive)[36,37]
Intermediate PS 2[i]	• Albumin-bound Paclitaxel/ Gemcitabine[15] • Capecitabine/Gemcitabine[16] • Cisplatin/Gemcitabine[9] • Cisplatin/Gemcitabine + Durvalumab[j,17] • FOLFOX	• Capecitabine[27] • Capecitabine + Bevacizumab[28] • CAPEOX[11] • CAPEOX + Bevacizumab[21,22] • Fluorouracil/Leucovorin • Fluorouracil/Leucovorin + Bevacizumab • FOLFIRI[23] • FOLFIRI + Bevacizumab • FOLFOX[25] • FOLFOX + Bevacizumab[22,26]	Useful in Certain Circumstances: • Entrectinib or Larotrectinib or Repotrectinib (if *NTRK* gene fusion-positive)[29,30,31,32] • Ipilimumab + Nivolumab (if MSI-H or dMMR, for intestinal type only)[j,33] • Pembrolizumab (if MSI-H, dMMR, or TMB-H [≥10 mut/Mb])[j,34,35] • Selpercatinib (if *RET* gene fusion-positive) • Dabrafenib/Trametinib (if *BRAF* V600E mutation-positive)[36,37]

Continued

[e] Due to the high toxicity of this regimen, bolus fluorouracil is often omitted.
[h] Good PS is defined as ECOG 0–1 with good biliary drainage and adequate nutritional intake, intermediate PS is defined as ECOG 2, and poor PS is defined as ECOG 3.
[i] Consider dose or schedule adjustments as clinically indicated.
[j] NCCN Guidelines for Management of Immune Checkpoint Inhibitor-Related Toxicities.
[k] While NCCN recognizes that there is high-level evidence supporting the use of NALIRIFOX over gemcitabine and albumin-bound paclitaxel, it should be recognized that this regimen does not appear to have an advantage over FOLFIRINOX.

References

Note: All recommendations are category 2A unless otherwise indicated.

Version 2.2026, 02/10/2026 © 2026 National Comprehensive Cancer Network® (NCCN®), All rights reserved. NCCN Guidelines® and this illustration may not be reproduced in any form without the express written permission of NCCN.

PLEASE NOTE that use of this NCCN Content is governed by the End-User License Agreement, and you MAY NOT distribute this Content or use it with any artificial intelligence model or tool.
Printed by Galya Basol Kochav on 2/14/2026 7:41:36 AM. Copyright © 2026 National Comprehensive Cancer Network, Inc. All Rights Reserved.

PRINCIPLES OF SYSTEMIC THERAPY

Metastatic Disease (First-Line Therapy)[h]			
	Pancreatobiliary/Mixed Type	**Intestinal Type**	**Targeted Systemic Therapies**
Poor PS 3	• Palliative and best supportive care, see NCCN Guidelines for Palliative Care • Capecitabine[38] • Fluorouracil/Leucovorin • Gemcitabine	• Palliative and best supportive care, see NCCN Guidelines for Palliative Care • Capecitabine[38] • Fluorouracil/Leucovorin[27]	Useful in Certain Circumstances: • Entrectinib or Larotrectinib or Repotrectinib (if *NTRK* gene fusion-positive)[29,30,31,32] • Ipilimumab + Nivolumab (if MSI-H or dMMR, for intestinal type only)[j,33] • Nivolumab (if MSI-H or dMMR, for intestinal type only)[j,39] • Pembrolizumab (if MSI-H, dMMR, or TMB-H [≥10 mut/Mb])[j,34,35] • Selpercatinib (if *RET* gene fusion-positive) • Dabrafenib/Trametinib (if *BRAF* V600E mutation-positive) (category 2B)[36,37]

[h] Good PS is defined as ECOG 0–1, with good biliary drainage and adequate nutritional intake, intermediate PS is defined as ECOG 2, and poor PS is defined as ECOG 3.
[j] NCCN Guidelines for Management of Immune Checkpoint Inhibitor-Related Toxicities.

References

Note: All recommendations are category 2A unless otherwise indicated.

Version 2.2026, 02/10/2026 © 2026 National Comprehensive Cancer Network® (NCCN®), All rights reserved. NCCN Guidelines® and this illustration may not be reproduced in any form without the express written permission of NCCN.

PLEASE NOTE that use of this NCCN Content is governed by the End-User License Agreement, and you MAY NOT distribute this Content or use it with any artificial intelligence model or tool.
Printed by Galya Basol Kochav on 2/14/2026 7:41:36 AM. Copyright © 2026 National Comprehensive Cancer Network, Inc. All Rights Reserved.

PRINCIPLES OF SYSTEMIC THERAPY

Therapy for Disease Progression[h]				
	Pancreatobiliary/Mixed Type		**Intestinal Type**	**Targeted Systemic Therapies**
Good PS 0–1	If prior Gemcitabine-based therapy: • Capecitabine[40] • CAPEOX[41] • Fluorouracil/Leucovorin[42] • Fluorouracil/Leucovorin/ Liposomal Irinotecan[43] • FOLFIRI[44-46] • FOLFIRINOX[18,47] or modified FOLFIRINOX[e] • FOLFOX[48] • OFF (Oxaliplatin/ Fluorouracil/ Leucovorin)[49]	If prior Fluoropyrimidine-based therapy: • Albumin-bound Paclitaxel/Gemcitabine[15] • Capecitabine/ Gemcitabine[16] • FOLFIRI or Fluorouracil/ Leucovorin/Liposomal Irinotecan (if no prior Irinotecan)[43-46] • Gemcitabine[5,6] If prior Oxaliplatin therapy: • FOLFIRI or Fluorouracil/ Leucovorin/Liposomal Irinotecan (if no prior Irinotecan)[43-46]	If prior Oxaliplatin-based therapy: • FOLFIRI[23] • FOLFIRI + Bevacizumab	Useful in Certain Circumstances: • Adagrasib or Sotorasib (if *KRAS G12C* mutation-positive)[50,51,52] • Cisplatin/Gemcitabine (only for known *BRCA1/2* mutations)[9] • Dabrafenib/Trametinib (if *BRAF* V600E mutation-positive)[36,37] • Entrectinib or Larotrectinib or Repotrectinib (if *NTRK* gene fusion-positive)[29,30,31,32] • Fam-trastuzumab deruxtecan-nxki (if HER2 positive [IHC3+ or IHC2+ with FISH *HER2* amplified])[53] • Selpercatinib (if *RET* gene fusion-positive)[54] If no prior immunotherapy: • Dostarlimab-gxly (if MSI-H or dMMR)[j,l,55] • Ipilimumab + Nivolumab (if MSI-H or dMMR)[j,33] • Pembrolizumab (if MSI-H, dMMR, or TMB-H [≥10 mut/Mb])[j,34,35]

Continued

[e] Due to the high toxicity of this regimen, bolus fluorouracil is often omitted.
[h] Good PS is defined as ECOG 0–1 with good biliary drainage and adequate nutritional intake, and intermediate PS is defined as ECOG 2, and poor PS is defined as ECOG 3.
[j] NCCN Guidelines for Management of Immune Checkpoint Inhibitor-Related Toxicities.
[l] For patients with recurrent or advanced tumors that have progressed on or following prior treatment and who have no satisfactory alternative treatment options. Patients who had received prior immune checkpoint inhibitor therapy were excluded from the dostarlimab-gxly clinical trial.

References

Note: All recommendations are category 2A unless otherwise indicated.

Version 2.2026, 02/10/2026 © 2026 National Comprehensive Cancer Network® (NCCN®), All rights reserved. NCCN Guidelines® and this illustration may not be reproduced in any form without the express written permission of NCCN.

PLEASE NOTE that use of this NCCN Content is governed by the End-User License Agreement, and you MAY NOT distribute this Content or use it with any artificial intelligence model or tool.
Printed by Galya Basol Kochav on 2/14/2026 7:41:36 AM. Copyright © 2026 National Comprehensive Cancer Network, Inc. All Rights Reserved.

PRINCIPLES OF SYSTEMIC THERAPY

Therapy for Disease Progression[h]			
	Pancreatobiliary/Mixed Type	**Intestinal Type**	**Targeted Systemic Therapies**
Intermediate PS 2[i]	<u>If prior Fluoropyrimidine-based therapy</u>: • Albumin-bound Paclitaxel/Gemcitabine[15] • Capecitabine/Gemcitabine[16] • Fluorouracil/Leucovorin/Liposomal Irinotecan (if no prior Irinotecan)[43] • FOLFIRI (if no prior Irinotecan)[44-46] • Gemcitabine[5,6] <u>If prior Gemcitabine-based therapy</u>: • Capecitabine[40] • CAPEOX[41] • Fluorouracil/Leucovorin[42] • Fluorouracil/Leucovorin/Liposomal Irinotecan[43] • FOLFIRI[44-46] • FOLFOX[48] • OFF[49] <u>If prior Oxaliplatin therapy</u>: • FOLFIRI or Fluorouracil/Leucovorin/Liposomal Irinotecan (if no prior Irinotecan)[43-46]	• Capecitabine • Capecitabine + Bevacizumab[28] • CAPEOX[11] • CAPEOX + Bevacizumab[22] • Fluorouracil/Leucovorin • Fluorouracil/Leucovorin + Bevacizumab[56,57] • FOLFOX[25] • FOLFOX + Bevacizumab[22,58] <u>If prior Oxaliplatin-based therapy:</u> • FOLFIRI[23] • FOLFIRI + Bevacizumab	<u>Useful in Certain Circumstances</u>: • Adagrasib or Sotorasib (if *KRAS G12C* mutation-positive)[50,51,52] • Cisplatin/Gemcitabine (only for known *BRCA1/2* mutations)[9] • Dabrafenib/Trametinib (if *BRAF* V600E mutation-positive)[36,37] • Entrectinib or Larotrectinib or Repotrectinib (if *NTRK* gene fusion-positive)[29,30,31,32] • Fam-trastuzumab deruxtecan-nxki (if HER2 positive [IHC3+ or IHC2+ with FISH *HER2* amplified])[53] • Selpercatinib (if *RET* gene fusion-positive)[54] <u>If no prior immunotherapy</u>: • Dostarlimab-gxly (if MSI-H or dMMR)[j,l,56] • Ipilimumab + Nivolumab (if MSI-H or dMMR)[j,33] • Nivolumab (if MSI-H or dMMR)[j,39] • Pembrolizumab (if MSI-H, dMMR, or TMB-H [≥10 mut/Mb])[j,34,35]

Continued

[h] Good PS is defined as ECOG 0–1 with good biliary drainage and adequate nutritional intake, and intermediate PS is defined as ECOG 2, and poor PS is defined as ECOG 3.
[i] Consider dose or schedule adjustments as clinically indicated.
[j] NCCN Guidelines for Management of Immune Checkpoint Inhibitor-Related Toxicities.
[l] For patients with recurrent or advanced tumors that have progressed on or following prior treatment and who have no satisfactory alternative treatment options. Patients who had received prior immune checkpoint inhibitor therapy were excluded from the dostarlimab-gxly clinical trial.

References

Note: All recommendations are category 2A unless otherwise indicated.

Version 2.2026, 02/10/2026 © 2026 National Comprehensive Cancer Network® (NCCN®), All rights reserved. NCCN Guidelines® and this illustration may not be reproduced in any form without the express written permission of NCCN.

PLEASE NOTE that use of this NCCN Content is governed by the End-User License Agreement, and you MAY NOT distribute this Content or use it with any artificial intelligence model or tool.
Printed by Galya Basol Kochav on 2/14/2026 7:41:36 AM. Copyright © 2026 National Comprehensive Cancer Network, Inc. All Rights Reserved.

PRINCIPLES OF SYSTEMIC THERAPY

Therapy for Disease Progression[h]			
	Pancreatobiliary/Mixed Type	**Intestinal Type**	**Targeted Systemic Therapies**
Poor PS 3	• Palliative and best supportive care, see NCCN Guidelines for Palliative Care If prior Fluoropyrimidine-based therapy: • Gemcitabine[5,6] If prior Gemcitabine-based therapy: • Capecitabine (category 2B)[40] • Fluorouracil/Leucovorin (category 2B)[42]	• Palliative and best supportive care, see NCCN Guidelines for Palliative Care • Capecitabine • Fluorouracil/Leucovorin[59]	Useful in Certain Circumstances: • Adagrasib or Sotorasib (if *KRAS G12C* mutation-positive)[49,50,51] • Dabrafenib/Trametinib (if *BRAF* V600E mutation-positive)[36,37] • Entrectinib or Larotrectinib or Repotrectinib (if *NTRK* gene fusion-positive)[29,30,31,32] • Selpercatinib (if *RET* gene fusion-positive)[54] If no prior immunotherapy: • Dostarlimab-gxly (if MSI-H or dMMR)[j,l,55] • Ipilimumab + Nivolumab (if MSI-H or dMMR)[j,33] • Nivolumab (if MSI-H or dMMR)[j,39] • Pembrolizumab (if MSI-H, dMMR, or TMB-H [≥10 mut/Mb])[j,34,35]

[h] Good PS is defined as ECOG 0–1 with good biliary drainage and adequate nutritional intake, intermediate PS is defined as ECOG 2, and poor PS is defined as ECOG 3.
[j] NCCN Guidelines for Management of Immune Checkpoint Inhibitor-Related Toxicities.
[l] For patients with recurrent or advanced tumors that have progressed on or following prior treatment and who have no satisfactory alternative treatment options. Patients who had received prior immune checkpoint inhibitor therapy were excluded from the dostarlimab-gxly clinical trial.

References

Note: All recommendations are category 2A unless otherwise indicated.

Version 2.2026, 02/10/2026 © 2026 National Comprehensive Cancer Network® (NCCN®), All rights reserved. NCCN Guidelines® and this illustration may not be reproduced in any form without the express written permission of NCCN.

PLEASE NOTE that use of this NCCN Content is governed by the End-User License Agreement, and you MAY NOT distribute this Content or use it with any artificial intelligence model or tool.
Printed by Galya Basol Kochav on 2/14/2026 7:41:36 AM. Copyright © 2026 National Comprehensive Cancer Network, Inc. All Rights Reserved.

PRINCIPLES OF SYSTEMIC THERAPY

Chemoradiation	
Pancreatobiliary, Mixed, and Intestinal Types	**Pancreatobiliary only**
Preferred • Capecitabine with concurrent RT[60,61] • Fluorouracil with concurrent RT[62,63]	Other Recommended • Gemcitabine with concurrent RT[60,61]

References

Note: All recommendations are category 2A unless otherwise indicated.

Version 2.2026, 02/10/2026 © 2026 National Comprehensive Cancer Network® (NCCN®), All rights reserved. NCCN Guidelines® and this illustration may not be reproduced in any form without the express written permission of NCCN.

PLEASE NOTE that use of this NCCN Content is governed by the End-User License Agreement, and you MAY NOT distribute this Content or use it with any artificial intelligence model or tool.
Printed by Galya Basol Kochav on 2/14/2026 7:41:36 AM. Copyright © 2026 National Comprehensive Cancer Network, Inc. All Rights Reserved.

PRINCIPLES OF SYSTEMIC THERAPY
REFERENCES

[1] Guo M, Beal EW, Miller ED, et al. Neoadjuvant therapy versus surgery first for ampullary carcinoma: A propensity score-matched analysis of the NCDB. J Surg Oncol 2021;123:1558-1567.
[2] Ghaneh P, Palmer D, Cicconi S, et al. Immediate surgery compared with short-course neoadjuvant gemcitabine plus capecitabine, FOLFIRINOX, or chemoradiotherapy in patients with borderline resectable pancreatic cancer (ESPAC5): a four-arm, multicentre, randomised, phase 2 trial. Lancet Gastroenterol Hepatol 2023;8:157-168.
[3] Morton D, Seymour M, Magill L, et al. Preoperative chemotherapy for operable colon cancer: Mature results of an international randomized controlled trial. J Clin Oncol 2023;41:1541–1552.
[4] Nassour I, Hynan LS, Christie A, et al. Association of adjuvant therapy with improved survival in ampullary cancer: A national cohort study. J Gastrointest Surg 2018;22:695-702.
[5] Neoptolemos JP, Moore MJ, Cox TF, et al. Effect of adjuvant chemotherapy with fluorouracil plus folinic acid or gemcitabine vs observation on survival in patients with resected periampullary adenocarcinoma: the ESPAC-3 periampullary cancer randomized trial [published correction appears in JAMA 2012;308:1861]. JAMA 2012;308:147-156.
[6] Oettle H, Neuhaus P, Hochhaus A, et al. Adjuvant chemotherapy with gemcitabine and long-term outcomes among patients with resected pancreatic cancer: the CONKO-001 randomized trial. JAMA 2013;310:1473-1481.
[7] Primrose JN, Fox RP, Palmer DH, et al. Capecitabine compared with observation in resected biliary tract cancer (BILCAP): a randomised, controlled, multicentre, phase 3 study [published correction appears in Lancet Oncol 2019;20:663-673]. Lancet Oncol 2019;20:663-673.
[8] Neoptolemos JP, Palmer DH, Ghaneh P, et al. Comparison of adjuvant gemcitabine and capecitabine with gemcitabine monotherapy in patients with resected pancreatic cancer (ESPAC-4): a multicentre, open-label, randomised, phase 3 trial. Lancet 2017;389:1011-1024.
[9] Valle J, Wasan H, Palmer DH, et al. Cisplatin plus gemcitabine versus gemcitabine for biliary tract cancer. N Engl J Med 2010;362:1273-1281.
[10] André T, Boni C, Mounedji-Boudiaf L, et al. Oxaliplatin, fluorouracil, and leucovorin as adjuvant treatment for colon cancer. N Engl J Med 2004;350:2343-2351.
[11] Overman MJ, Varadhachary GR, Kopetz S, et al. Phase II study of capecitabine and oxaliplatin for advanced adenocarcinoma of the small bowel and ampulla of Vater. J Clin Oncol 2009;27:2598-2603.
[12] Conroy T, Hammel P, Hebbar M, et al. FOLFIRINOX or gemcitabine as adjuvant therapy for pancreatic cancer. N Engl J Med 2018;379:2395-2406.
[13] Twelves C, Wong A, Nowacki MP, et al. Capecitabine as adjuvant treatment for stage III colon cancer. N Engl J Med 2005;352:2696-2704.
[14] Haller DG, Tabernero J, Maroun J, et al. Capecitabine plus oxaliplatin compared with fluorouracil and folinic acid as adjuvant therapy for stage III colon cancer. J Clin Oncol 2011;29:1465-1471.
[15] Von Hoff DD, Ervin T, Arena FP, et al. Increased survival in pancreatic cancer with nab-paclitaxel plus gemcitabine. N Engl J Med 2013;369:1691-1703.
[16] Cunningham D, Chau I, Stocken DD, et al. Phase III randomized comparison of gemcitabine versus gemcitabine plus capecitabine in patients with advanced pancreatic cancer. J Clin Oncol 2009;27:5513-5518.
[17] Oh D-Y, Ruth He A, Qin S, et al. Durvalumab plus Gemcitabine and Cisplatin in Advanced Biliary Tract Cancer. NEJM Evidence 2022;1:EVIDoa2200015.
[18] Conroy T, Desseigne F, Ychou M, et al. FOLFIRINOX versus gemcitabine for metastatic pancreatic cancer. N Engl J Med 2011;364:1817-1825.
[19] Stein SM, James ES, Deng Y, et al. Final analysis of a phase II study of modified FOLFIRINOX in locally advanced and metastatic pancreatic cancer. Br J Cancer 2016;114:737-743.
[20] Wainberg ZA, Melisi D, Macarulla T, et al. NALIRIFOX versus nab-paclitaxel and gemcitabine in treatment-naive patients with metastatic pancreatic ductal adenocarcinoma (NAPOLI 3): a randomised, open-label, phase 3 trial. Lancet 2023;402:1272-1281.
[21] Gulhati P, Raghav K, Shroff RT, et al. Bevacizumab combined with capecitabine and oxaliplatin in patients with advanced adenocarcinoma of the small bowel or ampulla of vater: A single-center, open-label, phase 2 study. Cancer 2017;123:1011-1017.
[22] Saltz LB, Clarke S, Díaz-Rubio E, et al. Bevacizumab in combination with oxaliplatin-based chemotherapy as first-line therapy in metastatic colorectal cancer: a randomized phase III study [published correction appears in J Clin Oncol 2008;26:3110] [published correction appears in J Clin Oncol 2009;27:653]. J Clin Oncol 2008;26:2013-2019.

Continued

Note: All recommendations are category 2A unless otherwise indicated.

Version 2.2026, 02/10/2026 © 2026 National Comprehensive Cancer Network® (NCCN®), All rights reserved. NCCN Guidelines® and this illustration may not be reproduced in any form without the express written permission of NCCN.

PLEASE NOTE that use of this NCCN Content is governed by the End-User License Agreement, and you MAY NOT distribute this Content or use it with any artificial intelligence model or tool.
Printed by Galya Basol Kochav on 2/14/2026 7:41:36 AM. Copyright © 2026 National Comprehensive Cancer Network, Inc. All Rights Reserved.

PRINCIPLES OF SYSTEMIC THERAPY
REFERENCES

[23] Fuchs CS, Marshall J, Mitchell E, et al. Randomized, controlled trial of irinotecan plus infusional, bolus, or oral fluoropyrimidines in first-line treatment of metastatic colorectal cancer: results from the BICC-C Study. J Clin Oncol 2007;25:4779-4786.
[24] Falcone A, Ricci S, Brunetti I, et al. Phase III trial of infusional fluorouracil, leucovorin, oxaliplatin, and irinotecan (FOLFOXIRI) compared with infusional fluorouracil, leucovorin, and irinotecan (FOLFIRI) as first-line treatment for metastatic colorectal cancer: the Gruppo Oncologico Nord Ovest. J Clin Oncol 2007;25:1670-1676.
[25] Cheeseman SL, Joel SP, Chester JD, et al. A 'modified de Gramont' regimen of fluorouracil, alone and with oxaliplatin, for advanced colorectal cancer. Br J Cancer 2002;87:393-399.
[26] Venook AP, Niedzwiecki D, Lenz HJ, et al. Effect of first-line chemotherapy combined with cetuximab or bevacizumab on overall survival in patients with KRAS wild-type advanced or metastatic colorectal cancer: A randomized clinical trial. JAMA 2017;317:2392-2401.
[27] Van Cutsem E, Twelves C, Cassidy J, et al. Oral capecitabine compared with intravenous fluorouracil plus leucovorin in patients with metastatic colorectal cancer: results of a large phase III study. J Clin Oncol 2001;19:4097-4106.
[28] Cunningham D, Lang I, Marcuello E, et al. Bevacizumab plus capecitabine versus capecitabine alone in elderly patients with previously untreated metastatic colorectal cancer (AVEX): an open-label, randomised phase 3 trial. Lancet Oncol 2013;14:1077-1085.
[29] Doebele RC, Drilon A, Paz-Ares L, et al. Entrectinib in patients with advanced or metastatic NTRK fusion-positive solid tumours: integrated analysis of three phase 1-2 trials. Lancet Oncol 2020;21:271-282.
[30] Drilon A, Siena S, Ou SI, et al. Safety and antitumor activity of the multitargeted Pan-TRK, ROS1, and ALK inhibitor entrectinib: Combined results from two phase I trials (ALKA-372-001 and STARTRK-1). Cancer Discov 2017;7:400-409.
[31] Drilon A, Laetsch TW, Kummar S, et al. Efficacy of larotrectinib in TRK fusion-positive cancers in adults and children. N Engl J Med 2018;378:731-739.
[32] Solomon BJ, Drilon A, Lin JJ, et al. Repotrectinib in patients with NTRK fusion-positive advanced solid tumors, including non-small cell lung cancer: update from the phase 1/2 TRIDENT-1 trial. Ann Oncol 2023;34:S787-S788.
[33] Overman MJ, Lonardi S, Wong KYM, et al. Durable clinical benefit with nivolumab plus ipilimumab in DNA mismatch repair-deficient/microsatellite instability-high metastatic colorectal cancer. J Clin Oncol 2018;36:773-779.
[34] Marabelle A, Le DT, Ascierto PA, et al. Efficacy of pembrolizumab in patients with noncolorectal high microsatellite instability/mismatch repair-deficient cancer: results from the phase 2 KEYNOTE-158 study. J Clin Oncol 2020;38:1-10.
[35] Lala M, Li TR, de Alwis DP, et al. A six-weekly dosing schedule for pembrolizumab in patients with cancer based on evaluation using modelling and simulation [published correction appears in Eur J Cancer 2021;144:400]. Eur J Cancer 2020;131:68-75.
[36] Salama AKS, Li S, Macrae ER, et al. Dabrafenib and trametinib in patients with tumors with BRAF V600E mutations: Results of the NCI-MATCH trial subprotocol H. J Clin Oncol 2020;38:3895-3904.
[37] Subbiah V, Lassen U, Élez E, et al. Dabrafenib plus trametinib in patients with BRAFV600E-mutated biliary tract cancer (ROAR): a phase 2, open-label, single-arm, multicentre basket trial. Lancet Oncol 2020;21:1234-1243.
[38] Cartwright TH, Cohn A, Varkey JA, et al. Phase II study of oral capecitabine in patients with advanced or metastatic pancreatic cancer. J Clin Oncol 2002;20:160-164.
[39] Overman MJ, McDermott R, Leach JL, et al. Nivolumab in patients with metastatic DNA mismatch repair-deficient or microsatellite instability-high colorectal cancer (CheckMate 142): an open-label, multicentre, phase 2 study. Lancet Oncol. 2017;18:1182-1191.
[40] Patt YZ, Hassan MM, Aguayo A, et al. Oral capecitabine for the treatment of hepatocellular carcinoma, cholangiocarcinoma, and gallbladder carcinoma. Cancer 2004;101:578-586.
[41] Xiong HQ, Varadhachary GR, Blais JC, et al. Phase 2 trial of oxaliplatin plus capecitabine (XELOX) as second-line therapy for patients with advanced pancreatic cancer. Cancer 2008;113:2046-2052.
[42] Gill S, Ko YJ, Cripps C, et al. PANCREOX: A randomized phase III study of fluorouracil/leucovorin with or without oxaliplatin for second-line advanced pancreatic cancer in patients who have received gemcitabine-based chemotherapy. J Clin Oncol 2016;34:3914-3920.
[43] Wang-Gillam A, Li CP, Bodoky G, et al. Nanoliposomal irinotecan with fluorouracil and folinic acid in metastatic pancreatic cancer after previous gemcitabine-based therapy (NAPOLI-1): a global, randomised, open-label, phase 3 trial. Lancet 2016;387:545-557.

Continued

Note: All recommendations are category 2A unless otherwise indicated.

Version 2.2026, 02/10/2026 © 2026 National Comprehensive Cancer Network® (NCCN®), All rights reserved. NCCN Guidelines® and this illustration may not be reproduced in any form without the express written permission of NCCN.

PLEASE NOTE that use of this NCCN Content is governed by the End-User License Agreement, and you MAY NOT distribute this Content or use it with any artificial intelligence model or tool.
Printed by Galya Basol Kochav on 2/14/2026 7:41:36 AM. Copyright © 2026 National Comprehensive Cancer Network, Inc. All Rights Reserved.

PRINCIPLES OF SYSTEMIC THERAPY
REFERENCES

[44] Neuzillet C, Hentic O, Rousseau B, et al. FOLFIRI regimen in metastatic pancreatic adenocarcinoma resistant to gemcitabine and platinum-salts. World J Gastroenterol 2012;18:4533-4541.
[45] Zaniboni A, Aitini E, Barni S, et al. FOLFIRI as second-line chemotherapy for advanced pancreatic cancer: a GISCAD multicenter phase II study. Cancer Chemother Pharmacol 2012;69:1641-1645.
[46] Chiorean EG, Guthrie KA, Philip PA, et al. Randomized phase II study of PARP inhibitor ABT-888 (veliparib) with modified FOLFIRI versus FOLFIRI as second-line treatment of metastatic pancreatic cancer: SWOG S1513. Clin Cancer Res 2021;27:6314-6322.
[47] Chiorean EG, Von Hoff DD, Tabernero J, et al. Second-line therapy after nab-paclitaxel plus gemcitabine or after gemcitabine for patients with metastatic pancreatic cancer [published correction appears in Br J Cancer 2016;115:e13]. Br J Cancer 2016;115:188-194.
[48] Lamarca A, Palmer DH, Wasan HS, et al. Second-line FOLFOX chemotherapy versus active symptom control for advanced biliary tract cancer (ABC-06): a phase 3, open-label, randomised, controlled trial. Lancet Oncol 2021;22:690-701.
[49] Pelzer U, Schwaner I, Stieler J, et al. Best supportive care (BSC) versus oxaliplatin, folinic acid and 5-fluorouracil (OFF) plus BSC in patients for second-line advanced pancreatic cancer: a phase III-study from the German CONKO-study group. Eur J Cancer 2011;47:1676-1681.
[50] Ou SI, Jänne PA, Leal TA, et al. First-in-Human Phase I/IB Dose-Finding Study of Adagrasib (MRTX849) in Patients With Advanced KRASG12C Solid Tumors (KRYSTAL-1). J Clin Oncol 2022;40:2530-2538.
[51] Hong DS, Fakih MG, Strickler JH, et al. KRASG12C Inhibition with Sotorasib in Advanced Solid Tumors. N Engl J Med 2020;383:1207-1217.
[52] Strickler JH, Satake H, George TJ, et al. Sotorasib in KRAS p.G12C-Mutated Advanced Pancreatic Cancer. N Engl J Med 2023;388:33-43.
[53] Meric-Bernstam F, Makker V, Oaknin A, et al. Efficacy and safety of trastuzumab deruxtecan in patients with HER2-expressing solid tumors: primary results from the DESTINY-PanTumor02 phase II trial. J Clin Oncol 2024;42:47-58.
[54] Subbiah V, Wolf J, Konda B, et al. Tumour-agnostic efficacy and safety of selpercatinib in patients with RET fusion-positive solid tumours other than lung or thyroid tumours (LIBRETTO-001): a phase 1/2, open-label, basket trial. Lancet Oncol 2022;23:1261-1273.
[55] André T, Berton D, Curigliano G, et al. Antitumor activity and safety of dostarlimab monotherapy in patients with mismatch repair deficient solid tumors: A nonrandomized controlled trial. JAMA Netw Open 2023;6:e2341165.
[56] Rothenberg ML, Oza AM, Bigelow RH, et al. Superiority of oxaliplatin and fluorouracil-leucovorin compared with either therapy alone in patients with progressive colorectal cancer after irinotecan and fluorouracil-leucovorin: interim results of a phase III trial. J Clin Oncol 2003;21:2059-2069.
[57] Rougier P, Van Cutsem E, Bajetta E, et al. Randomised trial of irinotecan versus fluorouracil by continuous infusion after fluorouracil failure in patients with metastatic colorectal cancer [published correction appears in Lancet 1998;352:1634]. Lancet 1998;352:1407-1412.
[58] Takayoshi K, Kusaba H, Uenomachi M, et al. Suggestion of added value by bevacizumab to chemotherapy in patients with unresectable or recurrent small bowel cancer. Cancer Chemother Pharmacol 2017;80:333-342.
[59] Andre T, Louvet C, Maindrault-Goebel F, et al. CPT-11 (irinotecan) addition to bimonthly, high-dose leucovorin and bolus and continuous-infusion 5-fluorouracil (FOLFIRI) for pretreated metastatic colorectal cancer. GERCOR. Eur J Cancer 1999;35:1343-1347.
[60] Hurt CN, Falk S, Crosby T, et al. Long-term results and recurrence patterns from SCALOP: a phase II randomised trial of gemcitabine- or capecitabine-based chemoradiation for locally advanced pancreatic cancer. Br J Cancer 2017;116:1264-1270.
[61] Hurt CN, Mukherjee S, Bridgewater J, et al. Health-related quality of life in SCALOP, a randomized phase 2 trial comparing chemoradiation therapy regimens in locally advanced pancreatic cancer. Int J Radiat Oncol Biol Phys 2015;93:810-818.
[62] Mehta VK, Fisher GA, Ford JM, et al. Adjuvant chemoradiotherapy for "unfavorable" carcinoma of the ampulla of Vater: preliminary report. Arch Surg 2001;136:65-69.
[63] Bhatia S, Miller RC, Haddock MG, et al. Adjuvant therapy for ampullary carcinomas: the Mayo Clinic experience. Int J Radiat Oncol Biol Phys 2006;66:514-519.

Note: All recommendations are category 2A unless otherwise indicated.

Version 2.2026, 02/10/2026 © 2026 National Comprehensive Cancer Network® (NCCN®), All rights reserved. NCCN Guidelines® and this illustration may not be reproduced in any form without the express written permission of NCCN.

PLEASE NOTE that use of this NCCN Content is governed by the End-User License Agreement, and you MAY NOT distribute this Content or use it with any artificial intelligence model or tool.
Printed by Galya Basol Kochav on 2/14/2026 7:41:36 AM. Copyright © 2026 National Comprehensive Cancer Network, Inc. All Rights Reserved.

PRINCIPLES OF RADIATION THERAPY

General Principles:

- Patients with ampullary cancer are best treated by a multidisciplinary team.
- Prior to initiation of RT, staging is optimally determined with a CT abdomen with contrast and/or MRI with and without contrast.
- Recommendations for RT for patients with ampullary cancer are typically made based on four clinical scenarios:
  - Localized disease (neoadjuvant/adjuvant)
  - Locally advanced disease
  - Recurrent disease
  - Palliative care
- In these scenarios, the goal of delivering RT is to sterilize vessel margins, enhance the likelihood of a margin-negative resection, and/or provide adequate local control to prevent or delay progression or prevent local disease recurrence while minimizing the risk of RT exposure to surrounding organs at risk (OARs). Radiation can also be used to palliate pain and bleeding or relieve obstructive symptoms in patients who have progressed or recurred locally.

Note: All recommendations are category 2A unless otherwise indicated.

Version 2.2026, 02/10/2026 © 2026 National Comprehensive Cancer Network® (NCCN®), All rights reserved. NCCN Guidelines® and this illustration may not be reproduced in any form without the express written permission of NCCN.

PLEASE NOTE that use of this NCCN Content is governed by the End-User License Agreement, and you MAY NOT distribute this Content or use it with any artificial intelligence model or tool.
Printed by Galya Basol Kochav on 2/14/2026 7:41:36 AM. Copyright © 2026 National Comprehensive Cancer Network, Inc. All Rights Reserved.

PRINCIPLES OF RADIATION THERAPY
TREATMENT PLANNING: RADIATION DELIVERY

Simulation:
- For ampullary cancer, placement of fiducial markers may be useful for targeting purposes. Placement of fiducial markers directly into the tumor and/or periphery under EUS is preferred. Stents can assist with targeting; however, they can shift and are therefore less reliable than fiducials. In the adjuvant setting, strategically placed surgical clips may serve a similar purpose.
- Position patient supine with arms up in an immobilization device that will be custom-made for each patient. The simulation scan range should include the target structures and OARs.
- Unless there is a contraindication to IV contrast, CT simulation with 2–3 mm slices should be performed with IV contrast whenever feasible (assuming adequate kidney function). Multiphase IV contrast delivery is preferred whenever possible to facilitate disease delineation, where clinically appropriate. MRI imaging may be complimentary to CT in target delineation. Neutral contrast may also be utilized.
- Simulation and treatment of patient with nothing by mouth (NPO) may facilitate setup reproducibility. If the patient receives oral contrast, consider giving the same volume of water prior to treatment each day to mimic simulation anatomy.

Motion Management[1]:
- A motion management strategy should be considered.
- Respiratory motion should be accounted for in determining the internal target volume (ITV). These strategies may include using a four-dimensional computed tomography (4D-CT) scan, respiratory gating, breath-hold, respiratory tracking, or abdominal compression.

Planning, Dose, and Fractionation:
- Three-dimensional conformal radiation therapy (3D-CRT), intensity-modulated RT (IMRT), and stereotactic body RT (SBRT) can result in improved planning target volume (PTV) coverage with decreased dose to OARs.[2,3] IMRT is preferred over 3D-CRT for conventional or hypofractionated RT, particularly if dose escalation is being considered. The exact planning strategy used should be individualized to patient anatomy, clinical scenario, treatment goals, and dose goals.
- It is imperative to evaluate the dose-volume histogram (DVH) of the target structures and the critical OARs such as the duodenum, stomach, liver, kidneys, spinal cord, and bowel. See Table 1. Normal Tissue Dose Volume Recommendations for Chemoradiation Utilizing Conventional Fractionation (AMP-F 5 of 6). No definitive dose constraints for SBRT currently exist; however, they are emerging and are dependent on a variety of factors including dose per fraction and total dose.
- While these examples of limits are empirical they differ based on dose per fraction, total dose delivered, and disease status (adjuvant vs. unresectable).

References

Note: All recommendations are category 2A unless otherwise indicated.

Version 2.2026, 02/10/2026 © 2026 National Comprehensive Cancer Network® (NCCN®), All rights reserved. NCCN Guidelines® and this illustration may not be reproduced in any form without the express written permission of NCCN.

PLEASE NOTE that use of this NCCN Content is governed by the End-User License Agreement, and you MAY NOT distribute this Content or use it with any artificial intelligence model or tool.
Printed by Galya Basol Kochav on 2/14/2026 7:41:36 AM. Copyright © 2026 National Comprehensive Cancer Network, Inc. All Rights Reserved.

PRINCIPLES OF RADIATION THERAPY RECOMMENDATIONS BASED ON TREATMENT SETTING[a]

Localized Disease:

- Data are limited to support specific treatment options for localized ampullary cancer; most data supporting the role of RT in this setting are in the adjuvant setting.
- Neoadjuvant therapy may facilitate margin-negative resection in more advanced cases and may improve OS, but ideally should be conducted as a clinical trial (Principles of Systemic Therapy [AMP-E]).
- The optimal timing for surgical resection following neoadjuvant RT has not been firmly established.
- RT Dosing/Planning:
  - For chemoradiation, the following RT doses have been reported: 45–54 Gy in 1.8–2.0 Gy fractions (in 25–30 total fractions) (doses higher than 54 Gy may be considered in a clinical trial).
  - Elective nodal irradiation (ENI) is usually recommended for localized/locally advanced disease.

Neoadjuvant/Adjuvant[b,4]:

- After resection, patients often receive adjuvant RT for one or more features that portend high risk for local recurrence (eg, ≥T3, positive nodes, positive margins, poor differentiation, perineural/perivascular invasion).
- If no prior neoadjuvant therapy and no evidence of recurrence or metastatic disease after resection, RT is included in the following adjuvant therapy option:
  - Adjuvant chemotherapy followed by chemoradiation ± subsequent chemotherapy (Principles of Systemic Therapy [AMP-E]).
- RT Dosing/Planning:
  - For chemoradiation, RT dose generally consists of 45–50.4 Gy in 1.8–2.0 Gy fractions (in 25–28 total fractions) to the tumor bed, surgical anastomoses (hepaticojejunostomy and gastrojejunostomy may be omitted if clinically appropriate), and adjacent lymph node basins, with potential dose escalation to the high-risk regions, if clinically appropriate. Careful attention to the bowel and stomach dose is warranted and normal tissue dose constraints should always be considered.
  - Several pancreatic clinical trials (RTOG) now refer to atlases to assist with contouring and adjuvant RT planning: (https://www.nrgoncology.org/About-Us/Center-for-Innovation-in-Radiation-Oncology). Target design is similar in ampullary cancers.
  - Preoperative CT scans and strategically placed surgical clips may be used to determine the tumor bed, ideally with the surgeon's assistance.

[a] It is not known whether one regimen is necessarily more effective than another in the four clinical scenarios mentioned above. Therefore, the following recommendations are given as examples of commonly used regimens. However, other recommendations based on similar principles are acceptable.
[b] Adjuvant options listed apply only to patients who did not receive prior neoadjuvant therapy. For those who received prior neoadjuvant therapy, the adjuvant therapy options are dependent on the response to neoadjuvant therapy and other clinical considerations.

References

Note: All recommendations are category 2A unless otherwise indicated.

Version 2.2026, 02/10/2026 © 2026 National Comprehensive Cancer Network® (NCCN®), All rights reserved. NCCN Guidelines® and this illustration may not be reproduced in any form without the express written permission of NCCN.

PLEASE NOTE that use of this NCCN Content is governed by the End-User License Agreement, and you MAY NOT distribute this Content or use it with any artificial intelligence model or tool.
Printed by Galya Basol Kochav on 2/14/2026 7:41:36 AM. Copyright © 2026 National Comprehensive Cancer Network, Inc. All Rights Reserved.

PRINCIPLES OF RADIATION THERAPY
RECOMMENDATIONS BASED ON TREATMENT SETTING

Locally Advanced:
- Albeit rare, the goal of RT is to prevent or delay local progression (that may result in pain or local obstructive symptoms) and facilitate local disease control, and in some instances help facilitate R0 resection in patients considered for surgery.
- Data are limited to support specific RT recommendations for locally advanced disease. Options may include:
  - Chemoradiation if not a candidate for combination chemotherapy.
  - Induction chemotherapy followed by chemoradiation in select patients (locally advanced without systemic metastases).
- RT Dosing/Planning:
  - For chemoradiation, RT dose generally consists of 45–56 Gy in 1.8–2.2 Gy fractions (in 25–30 total fractions).

Recurrent Ampullary Cancer (resection bed):
- Data are limited to support specific RT recommendations for locally recurrent ampullary cancer; the options for patients with recurrent, unresectable disease may include:
  - Chemoradiation[5] in selected patients who are not candidates for induction chemotherapy.
  - Induction chemotherapy followed by chemoradiation or SBRT (Principles of Systemic Therapy [AMP-E]).
- RT Dosing/Planning:
  - For chemoradiation, RT dose generally consists of 45–56 Gy in 1.8–2.2 Gy fractions (in 25–30 total fractions).
  - There are limited data to support a specific RT dosing for SBRT[c]; therefore, for recurrent ampullary cancer, it should be used as part of a clinical trial or at an experienced, high-volume center.
  - However, caution is warranted when using higher doses and normal tissue constraints must be respected. This approach is optimally performed in the setting of a clinical trial.

Palliative
- The goal of palliative RT is often to relieve pain and bleeding and/or ameliorate local obstructive symptoms in patients with non-metastatic or metastatic disease. See Principles of Palliation and Supportive Care (AMP-G).
  - Non-Metastatic Disease: Palliative RT can be considered for patients who are older and/or not candidates for definitive therapy due to poor PS or comorbidities.
  - Metastatic Disease:
    - Metastatic sites causing pain (ie, osseous) may be palliated with a short course of RT. SBRT may be used in select cases for metastatic sites, including oligometastatic disease.
    - RT is reasonable for patients with metastatic disease who require local palliation for symptoms such as obstruction, pain refractory to analgesic therapy, or bleeding.
- RT Dosing/Planning:
  - Palliative RT is commonly used, although specific dose and fractionation recommendations should take into account burden of metastatic disease, normal tissue tolerance, and expected survival.

[c] SBRT should be delivered at an experienced, high-volume center with technology that allows for image-guided RT or in a clinical trial. SBRT should be avoided if direct invasion of the bowel or stomach is observed on CT, MRI, and/or endoscopy.

References

Note: All recommendations are category 2A unless otherwise indicated.

Version 2.2026, 02/10/2026 © 2026 National Comprehensive Cancer Network® (NCCN®), All rights reserved. NCCN Guidelines® and this illustration may not be reproduced in any form without the express written permission of NCCN.

PLEASE NOTE that use of this NCCN Content is governed by the End-User License Agreement, and you MAY NOT distribute this Content or use it with any artificial intelligence model or tool.
Printed by Galya Basol Kochav on 2/14/2026 7:41:36 AM. Copyright © 2026 National Comprehensive Cancer Network, Inc. All Rights Reserved.

PRINCIPLES OF RADIATION THERAPY

Table 1: Normal Tissue Dose Volume Recommendations for Chemoradiation Utilizing Conventional Fractionation

Organs at Risk (OARs)	Neoadjuvant/Definitive/Palliative and Recurrent Recommendations[d]	Adjuvant Recommendations[e]
Kidney (right and left)	Not more than 30% of the total volume can receive ≥18 Gy. If only one kidney is functional, not more than 10% of the volume can receive ≥18 Gy.	For 3D-CRT plans in patients with two normally functioning kidneys, at least 50% of the right kidney and at least 65% of the left kidney must receive <18 Gy. For IMRT planning, mean dose to bilateral kidneys must be <18 Gy. If only one kidney is present, not more than 15% of the volume of that kidney can receive ≥18 Gy and not more than 30% can receive ≥14 Gy.
Stomach, duodenum, and jejunum	Max dose 55 Gy.	Max dose ≤54 Gy; <10% of each organ volume can receive between 50 and 53.99 Gy; <15% of the volume of each organ can receive between 45 and 49.99 Gy.
Liver	Mean dose cannot exceed 30 Gy.	Mean liver dose must be ≤25 Gy.
Spinal cord	Max dose to a volume of at least 0.03 cc must be ≤45 Gy.	Max dose ≤45 Gy.

[d] Adapted from RTOG 1102 (IMRT, 2.2–54 Gy).
[e] Adapted from RTOG 0848 (3D or IMRT).

Note: All recommendations are category 2A unless otherwise indicated.

Version 2.2026, 02/10/2026 © 2026 National Comprehensive Cancer Network® (NCCN®), All rights reserved. NCCN Guidelines® and this illustration may not be reproduced in any form without the express written permission of NCCN.

PLEASE NOTE that use of this NCCN Content is governed by the End-User License Agreement, and you MAY NOT distribute this Content or use it with any artificial intelligence model or tool.
Printed by Galya Basol Kochav on 2/14/2026 7:41:36 AM. Copyright © 2026 National Comprehensive Cancer Network, Inc. All Rights Reserved.

PRINCIPLES OF RADIATION THERAPY
REFERENCES

[1] Keall PJ, Mageras GS, Balter JM, et al. The management of respiratory motion in radiation oncology report of AAPM task group 76. Med Phys 2006;33:3874-3900.
[2] Spalding AC, Jee KW, Vineberg K, et al. Potential for dose-escalation and reduction of risk in pancreatic cancer using IMRT optimization with lexicographic ordering and gEUD-based cost functions. Med Phys 2007;34:521-529.
[3] Yovino S, Poppe M, Jabbour S, et al. Intensity-modulated radiation therapy significantly improves acute gastrointestinal toxicity in pancreatic and ampullary cancers. Int J Radiat Oncol Biol Phys 2011;79:158-162.
[4] Jabbour SK, Mulvihill D. Defining the role of adjuvant therapy: ampullary and duodenal adenocarcinoma. Semin Radiat Oncol 2014;24:85-93.
[5] Huguet F, Girard N, Guerche CS, et al. Chemoradiotherapy in the management of locally advanced pancreatic carcinoma: A qualitative systematic review. J Clin Oncol 2009;27:2269-2277.

Note: All recommendations are category 2A unless otherwise indicated.

Version 2.2026, 02/10/2026 © 2026 National Comprehensive Cancer Network® (NCCN®), All rights reserved. NCCN Guidelines® and this illustration may not be reproduced in any form without the express written permission of NCCN.

PLEASE NOTE that use of this NCCN Content is governed by the End-User License Agreement, and you MAY NOT distribute this Content or use it with any artificial intelligence model or tool.
Printed by Galya Basol Kochav on 2/14/2026 7:41:36 AM. Copyright © 2026 National Comprehensive Cancer Network, Inc. All Rights Reserved.

PRINCIPLES OF PALLIATION AND SUPPORTIVE CARE[a]

Objective: Prevent and ameliorate suffering while ensuring optimal quality of life.

Symptom	Therapy
Biliary obstruction	• Endoscopic biliary metal stent (preferred method) • Percutaneous biliary drainage with subsequent internalization • Open biliary-enteric bypass
Gastric outlet/duodenal obstruction	• Good PS ▸ Gastrojejunostomy (open or laparoscopic) ± G/J-tube ▸ Consider enteral stent[a] • Poor PS ▸ Venting percutaneous endoscopic gastrostomy (PEG) tube for gastric decompression ▸ Enteral stent[a]
Thromboembolic disease[b]	• Low-molecular-weight heparin preferred over warfarin[c] • Consider direct oral anticoagulants for patients without luminal tumors
Bleeding from the primary tumor site	• Therapeutic endoscopy, if clinically indicated • RT, if not previously done • Angiography with embolization, if clinically indicated
Pain (NCCN Guidelines for Adult Cancer Pain)	• Early referral to pain or palliative care specialist to determine the best treatment option • Opioids with or without neurolysis • EUS-guided celiac plexus neurolysis (fluoroscopic- or CT-guided if unavailable) • Celiac plexus radiation/radiosurgery[d] • SBRT • Severe tumor-associated abdominal pain unresponsive to optimal, around-the-clock analgesic administration, or if the patient experiences undesirable analgesic-associated side effects ▸ High-intensity focused ultrasound ▸ Consider palliative radiation with or without chemotherapy if not already given as part of the primary therapy regimen. See Principles of Radiation Therapy (AMP-F). ▸ Intrathecal drug delivery
Depression and malnutrition (NCCN Guidelines for Supportive Care)	• Formal Palliative Medicine Service evaluation when available[e,f] • Nutritional evaluation with a registered dietitian when available • Pancreatic enzyme replacement in the case of exocrine pancreatic insufficiency ▸ Starting dose of at least 48,000 units lipase with meals (preferably 72,000)

[a] Placement of an enteral stent is particularly important for patients with poor PS and should be done after biliary drainage is assured.
[b] NCCN Guidelines for Cancer-Associated Venous Thromboembolic Disease.
[c] A randomized trial examining the effects of prophylactic low-molecular-weight heparin showed a decrease in venous thromboembolism but no effect on survival (Pelzer U, et al. J Clin Oncol 2015;33:2028-2034).
[d] Yaacov RL, et al. J Clin Oncol 2023;41(Suppl):Abstract 662; Jacobson G, et al. BMJ Open 2022;12:e050169.
[e] Palliative surgical procedures are best reserved for patients with a longer life expectancy.
[f] Consider encouraging advanced care planning.

Note: All recommendations are category 2A unless otherwise indicated.

Version 2.2026, 02/10/2026 © 2026 National Comprehensive Cancer Network® (NCCN®), All rights reserved. NCCN Guidelines® and this illustration may not be reproduced in any form without the express written permission of NCCN.

PLEASE NOTE that use of this NCCN Content is governed by the End-User License Agreement, and you MAY NOT distribute this Content or use it with any artificial intelligence model or tool.
Printed by Galya Basol Kochav on 2/14/2026 7:41:36 AM. Copyright © 2026 National Comprehensive Cancer Network, Inc. All Rights Reserved.

Table 1. **Definitions for T, N, M**
American Joint Committee on Cancer (AJCC) TNM Staging of Ampulla of Vater (8th ed., 2017)

T	**Primary Tumor**
TX	Primary tumor cannot be assessed
T0	No evidence of primary tumor
Tis	Carcinoma *in situ*
T1	Tumor limited to ampulla of Vater or sphincter of Oddi or tumor invades beyond the sphincter of Oddi (perisphincteric invasion) and/or into the duodenal submucosa
T1a	Tumor limited to ampulla of Vater or sphincter of Oddi
T1b	Tumor invades beyond the sphincter of Oddi (perisphincteric invasion) and/or into the duodenal submucosa
T2	Tumor invades into the muscularis propria of the duodenum
T3	Tumor directly invades the pancreas (up to 0.5 cm) or tumor extends more than 0.5 cm into the pancreas, or extends into peripancreatic or periduodenal tissue or duodenal serosa without involvement of the celiac axis or superior mesenteric artery
T3a	Tumor directly invades pancreas (up to 0.5 cm)
T3b	Tumor extends more than 0.5 cm into the pancreas, or extends into peripancreatic tissue or periduodenal tissue or duodenal serosa without involvement of the celiac axis or superior mesenteric artery
T4	Tumor involves the celiac axis, superior mesenteric artery, and/or common hepatic artery, irrespective of size

N	**Regional Lymph Nodes**
NX	Regional lymph nodes cannot be assessed
N0	No regional lymph node metastasis
N1	Metastasis to one to three regional lymph nodes
N2	Metastasis to four or more regional lymph nodes

M	**Distant Metastasis**
M0	No distant metastasis
M1	Distant metastasis

Table 2. **AJCC Prognostic Groups**

	T	N	M
Stage 0	Tis	N0	M0
Stage IA	T1a	N0	M0
Stage IB	T1b, T2	N0	M0
Stage IIA	T3a	N0	M0
Stage IIB	T3b	N0	M0
Stage IIIA	T1a, T1b, T2, T3a, T3b	N1	M0
Stage IIIB	T4	Any N	M0
	Any T	N2	M0
Stage IV	Any T	Any N	M1

Table 3. **Histologic Grade**

G	G Definition
GX	Grade cannot be assessed
G1	Well differentiated
G2	Moderately differentiated
G3	Poorly differentiated

Used with permission of the American College of Surgeons, Chicago, Illinois. The original source for this information is the AJCC Cancer Staging Manual, Eighth Edition (2017) published by Springer International Publishing.

Note: All recommendations are category 2A unless otherwise indicated.

Version 2.2026, 02/10/2026 © 2026 National Comprehensive Cancer Network® (NCCN®), All rights reserved. NCCN Guidelines® and this illustration may not be reproduced in any form without the express written permission of NCCN.

PLEASE NOTE that use of this NCCN Content is governed by the End-User License Agreement, and you MAY NOT distribute this Content or use it with any artificial intelligence model or tool.
Printed by Galya Basol Kochav on 2/14/2026 7:41:36 AM. Copyright © 2026 National Comprehensive Cancer Network, Inc. All Rights Reserved.

ABBREVIATIONS

3D-CRT	three-dimensional conformal radiation therapy
4D-CT	four-dimensional computed tomography
CAP	College of American Pathologists
CEA	carcinoembryonic antigen
DFS	disease-free survival
dMMR	mismatch repair deficient
DVH	dose-volume histogram
DWI	diffusion-weighted echo
EGD	esophagogastroduodenoscopy
ENI	elective nodal irradiation
ERCP	endoscopic retrograde cholangiopancreatography
EUS	endoscopic ultrasound
FISH	fluorescence in situ hybridization
FRFSE	fast relaxation fast spin-echo sequence
FSE	fast spin echo
G/J-tube	gastrostomy/jejunostomy tube
GRE	gradient echo
H&P	history and physical
IHC	immunohistochemistry
IAPN	intra-ampullary papillary tubular neoplasm
IMRT	intensity-modulated radiation therapy
ITV	internal target volume
MDCT	multi-detector computed tomography
MIP	maximum intensity projection
MPV	main portal vein
MRCP	magnetic resonance cholangiopancreatography
MSI	microsatellite instability
MSI-H	microsatellite instability-high
NGS	next-generation sequencing
NPO	nothing by mouth
OAR	organ at risk
OS	overall survival
PEG	percutaneous endoscopic gastrostomy
PS	performance status
PTC	percutaneous transhepatic cholangiography
PTV	planning target volume
PV	portal vein
SBRT	stereotactic body radiation therapy
SEMS	self-expanding metal stent
SMA	superior mesenteric artery
SMV	superior mesenteric vein
SSFSE	single-shot fast spin echo
TMB	tumor mutational burden
TMB-H	tumor mutational burden-high
TNM	tumor node metastasis

Version 2.2026, 02/10/2026 © 2026 National Comprehensive Cancer Network® (NCCN®), All rights reserved. NCCN Guidelines® and this illustration may not be reproduced in any form without the express written permission of NCCN.

PLEASE NOTE that use of this NCCN Content is governed by the End-User License Agreement, and you MAY NOT distribute this Content or use it with any artificial intelligence model or tool.
Printed by Galya Basol Kochav on 2/14/2026 7:41:36 AM. Copyright © 2026 National Comprehensive Cancer Network, Inc. All Rights Reserved.

NCCN Categories of Evidence and Consensus	
Category 1	Based upon high-level evidence (≥1 randomized phase 3 trials or high-quality, robust meta-analyses), there is uniform NCCN consensus (≥85% support of the Panel) that the intervention is appropriate.
Category 2A	Based upon lower-level evidence, there is uniform NCCN consensus (≥85% support of the Panel) that the intervention is appropriate.
Category 2B	Based upon lower-level evidence, there is NCCN consensus (≥50%, but <85% support of the Panel) that the intervention is appropriate.
Category 3	Based upon any level of evidence, there is major NCCN disagreement that the intervention is appropriate.

All recommendations are category 2A unless otherwise indicated.

NCCN Categories of Preference	
Preferred	Interventions that are based on superior efficacy, safety, and evidence; and, when appropriate, affordability.
Other recommended	Other interventions that may be somewhat less efficacious, more toxic, or based on less mature data; or significantly less affordable for similar outcomes.
Useful in certain circumstances	Other interventions that may be used for selected patient populations (defined with recommendation).

All recommendations are considered appropriate.

Note: All recommendations are category 2A unless otherwise indicated.

Version 2.2026, 02/10/2026 © 2026 National Comprehensive Cancer Network® (NCCN®), All rights reserved. NCCN Guidelines® and this illustration may not be reproduced in any form without the express written permission of NCCN.

PLEASE NOTE that use of this NCCN Content is governed by the End-User License Agreement, and you MAY NOT distribute this Content or use it with any artificial intelligence model or tool.
Printed by Galya Basol Kochav on 2/14/2026 7:41:36 AM. Copyright © 2026 National Comprehensive Cancer Network, Inc. All Rights Reserved.

Discussion

This discussion corresponds to the NCCN Guidelines for Ampullary Adenocarcinoma. Last updated on February 10, 2026.

Table of Contents

Overview MS-2
Guidelines Update Methodology MS-3
Literature Search Criteria and Guidelines Update Methodology MS-3
Sensitive/Inclusive Language Usage MS-3
Genetics of Ampullary Cancer MS-4
Clinical Presentation and Workup MS-4
Ampullary Adenoma MS-5
Ampullary Adenocarcinoma MS-6
- Treatment of Ampullary Adenocarcinoma MS-6
  - Treatment of Localized Disease MS-6
  - Treatment of Metastatic Disease MS-12
  - Treatment for Disease Progression MS-14

Palliative and Best Supportive Care MS-16
Summary MS-16
References MS-17

Version 2.2026 © 2026 National Comprehensive Cancer Network© (NCCN©), All rights reserved. NCCN Guidelines® and this illustration may not be reproduced in any form without the express written permission of NCCN.

PLEASE NOTE that use of this NCCN Content is governed by the End-User License Agreement, and you MAY NOT distribute this Content or use it with any artificial intelligence model or tool.
Printed by Galya Basol Kochav on 2/14/2026 7:41:36 AM. Copyright © 2026 National Comprehensive Cancer Network, Inc. All Rights Reserved.

Overview

Ampullary cancers are defined as tumors originating from the ampulla of Vater (formed by three anatomical components: the ampulla, the intraduodenal portion of the bile duct, and the intraduodenal portion of the pancreatic duct), while periampullary cancers may arise from locations encompassing the head of the pancreas, distal bile duct, duodenum, or ampulla of Vater.[1] Although relatively rare, accounting for only 0.2% of gastrointestinal malignancies and 6% of all periampullary cancers, ampullary adenocarcinoma is an important entity given the pathologic variations and associated prognosis.[2] The 5-year overall survival (OS) for ampullary cancer is between 35% and 50%; however, prognosis can vary greatly based on a variety of factors such as patient age, TNM (tumor, node, metastasis) classification, differentiation, grade, and treatment modality received.[3-9] For example, the 5-year OS for AJCC 7th Edition stage I, stage II, and stage III + IV ampullary cancers is 64%, 27%, and 17%, respectively.[7] Similar to other malignancies, distant metastatic disease bodes a poor prognosis for ampullary cancer.[3] Regardless, ampullary tumors generally have a more favorable outcome when compared to other periampullary malignancies.[4,6,7,10-15] In a single-institutional review of 2564 periampullary cancers, the median survival for ampullary cancer was 47 months compared to 19, 23, and 54 months for pancreatic, biliary, and duodenal cancer, respectively.[10] Early detection might partially contribute to this prognostic pattern.

The ampulla of Vater is an anatomically complex region, and distinction of periampullary tumors based on site of origin is particularly challenging, especially for large tumors that have invaded surrounding organs at presentation.[16,17] The ampulla of Vater is comprised of two mucosal tissue types: pancreatobiliary ductal mucosa and intestinal mucosa. Therefore, ampullary cancer can be divided into two histologic subtypes: pancreatobiliary subtype and intestinal subtype.[18] The proportion of each subtype varies widely between study populations.[16,19-22] CDX2 and MUC1 are useful biomarkers to distinguish the two subtypes (pancreatobiliary subtype: CDX2 negative, MUC1 positive; intestinal subtype: CDX2 positive, MUC1 negative) and have been shown to be independent prognostic factors.[19-22] Other biomarkers that have been proven useful in making this distinction are MUC2 and CK20.[21-23] The utility of these biomarkers, however, is limited by staining method (hematoxylin and eosin [H&E] vs. immunohistochemistry [IHC]), staining positivity threshold, and subjective pathologists' assessment. It should be noted that a significant proportion of ampullary adenocarcinomas may be of mixed phenotype.[23,24] Thus, the Panel recommends reporting of histologic subtypes as pancreatobiliary, intestinal, or mixed, with the predominant pattern noted in the pathology report for the mixed subtype for data collection and future analysis. Each ampullary cancer subtype seems to resemble its periampullary counterpart in terms of biological behavior and prognosis, with the pancreatobiliary subtype demonstrating higher lymph node involvement and worse survival than the intestinal subtype.[13,18,20,24-26] In a retrospective study of 95 ampullary cancers and 206 matching periampullary cancers, the OS of pancreatobiliary subtype was comparable to that of pancreatic cancer (25 vs. 14 months; $P = .123$), but worse than that for intestinal subtype (25 vs. 98 months; $P < .001$).[25]

Systemic therapy is used in all stages of ampullary cancer. This includes neoadjuvant therapy for resectable or borderline resectable disease (albeit used more rarely compared to pancreatic cancer), adjuvant therapy, and first-line or subsequent-line therapy for locally advanced, metastatic, and recurrent disease. Data for systemic therapy in ampullary cancer are very limited; the only phase III randomized trial to date that enrolled a relatively large number of patients with ampullary cancer was ESPAC-3, which tested 5-fluorouracil (5-FU) + leucovorin versus gemcitabine in the adjuvant setting.[27] Thus, the recommendations for systemic therapy options in ampullary cancer are extrapolated from data in the setting of pancreatic cancer, colorectal cancer, and biliary tract cancer, as well as

Version 2.2026 © 2026 National Comprehensive Cancer Network© (NCCN©), All rights reserved. NCCN Guidelines® and this illustration may not be reproduced in any form without the express written permission of NCCN.

PLEASE NOTE that use of this NCCN Content is governed by the End-User License Agreement, and you MAY NOT distribute this Content or use it with any artificial intelligence model or tool.
Printed by Galya Basol Kochav on 2/14/2026 7:41:36 AM. Copyright © 2026 National Comprehensive Cancer Network, Inc. All Rights Reserved.

Panel members' clinical experience. Often, systemic therapy recommendations for pancreatobiliary/mixed type are derived from pancreatic or biliary tract cancer, while those for intestinal type are derived from colorectal cancer (see the NCCN Clinical Practice Guidelines in Oncology [NCCN Guidelines®] for Colon Cancer and NCCN Guidelines® for Small Bowel Adenocarcinoma, available at www.NCCN.org). Many regimens are put forth as likely options; however, their potential utility in individual patients must be carefully evaluated by the treating physicians based on interpretation of original trial data and drug risk/benefit profile.

Radiation therapy (RT) is another treatment modality that can be utilized in localized ampullary cancer, sometimes in combination with chemotherapy, but there is no high-level evidence to support its utility.[28,29] The goal of RT is to sterilize vessel margins, enhance the likelihood of a margin-negative resection, and/or provide adequate local control to prevent or delay progression or prevent local disease recurrence while minimizing the risk of RT exposure to surrounding organs at risk. Lastly, palliation and supportive care are warranted to prevent and ameliorate suffering while ensuring optimal quality of life for patients. For both of these modalities, recommendations are derived from the NCCN Guidelines for Pancreatic Adenocarcinoma (available at www.NCCN.org). Opioids with or without neurolysis or endoscopic ultrasound (EUS)-guided celiac plexus neurolysis can be utilized for pain management in ampullary cancer. Palliative RT with or without chemotherapy or high-intensity focused ultrasound (HIFU) can also be utilized for severe pain refractory to analgesic therapy, although the recommendation for HIFU is only supported by a small number of observational studies.[30]

Guidelines Update Methodology

The complete details of the Development and Update of the NCCN Guidelines are available at www.NCCN.org.

Literature Search Criteria and Guidelines Update Methodology

Prior to the update of this version of the NCCN Guidelines for Ampullary Adenocarcinoma, an electronic search of the PubMed database was performed to obtain key literature published since the previous Guidelines update, using the following search term: "ampullary cancer" OR "ampullary adenocarcinoma." The PubMed database was chosen because it remains the most widely used resource for medical literature and indexes peer-reviewed biomedical literature.

The search results were narrowed by selecting studies in humans published in English. Results were confined to the following article types: Clinical Trial, Phase III; Clinical Trial, Phase IV; Guideline; Practice Guideline; Randomized Controlled Trials; Meta-Analysis; Multicenter Study; Systematic Reviews; and Validation Studies. The data from key PubMed articles as well as articles from additional sources deemed relevant to these guidelines as discussed by the Panel during the Guidelines update have been included in this version of the Discussion section. Recommendations for which high-level evidence is lacking are based on the Panel's review of lower-level evidence and expert opinion.

Sensitive/Inclusive Language Usage

NCCN Guidelines strive to use language that advances the goals of equity, inclusion, and representation.[31] NCCN Guidelines endeavor to use language that is person-first; not stigmatizing; anti-racist, anti-classist, anti-misogynist, anti-ageist, anti-ableist, and anti-weight-biased; and inclusive of individuals of all sexual orientations and gender identities. NCCN Guidelines incorporate non-gendered language, instead focusing on organ-specific recommendations. This language is both more accurate and more inclusive and can help fully address the needs of individuals of all sexual orientations and gender identities. NCCN Guidelines will continue to use the terms *men*, *women*, *female*, and *male* when citing

Version 2.2026 © 2026 National Comprehensive Cancer Network© (NCCN©), All rights reserved. NCCN Guidelines® and this illustration may not be reproduced in any form without the express written permission of NCCN.

PLEASE NOTE that use of this NCCN Content is governed by the End-User License Agreement, and you MAY NOT distribute this Content or use it with any artificial intelligence model or tool.
Printed by Galya Basol Kochav on 2/14/2026 7:41:36 AM. Copyright © 2026 National Comprehensive Cancer Network, Inc. All Rights Reserved.

statistics, recommendations, or data from organizations or sources that do not use inclusive terms. Most studies do not report how sex and gender data are collected and use these terms interchangeably or inconsistently. If sources do not differentiate gender from sex assigned at birth or organs present, the information is presumed to predominantly represent cisgender individuals. NCCN encourages researchers to collect more specific data in future studies and organizations to use more inclusive and accurate language in their future analyses.

Genetics of Ampullary Cancer

Important genomic similarities and differences between ampullary cancer and other periampullary cancers exist. For example, the frequency of *KRAS* mutations seems to be comparable between ampullary cancer[32,33] and duodenal cancer[34,35]; however, it is much higher in pancreatic cancer (~30% to 40% vs. ~90%[36]). *KRAS* mutations have been suggested to be predictive of outcomes in ampullary cancer; however, their prognostic value over histologic subtype is questionable.[32,33] Although *KRAS* mutations appear more frequently in pancreatobiliary subtypes, the distribution across ampullary cancer subtypes is unclear since present studies include very small numbers of patients with different histologic subtypes.

Other somatic alterations that have been reported in ampullary cancer include mutations in *APC*, *TP53*, *CDKN2A*, *DPC4*, *ELF3*, *PIK3CA*, *SMAD4*, and *HER2* amplifications, and microsatellite instability (MSI).[37-41] Pathogenic mutations reported include *BRCA1/2*, *ATM*, *RAD50*, and *MUTYH*.[39,42] A genomic classification study using a large dataset of 3411 patients with periampullary cancers found high concordance between histologic ampullary cancer subtypes and their respective genomic categories. Specifically, the pancreatobiliary subtype has genomic signature similar to pancreatic adenocarcinoma, which is characterized by a high incidence of *KRAS* mutations. The intestinal subtype has genomic signature similar to colorectal adenocarcinoma and is characterized by mutations in *APC* and *PI3KCA*, higher tumor mutational burden (TMB), and DNA mismatch repair (MMR) deficiency (dMMR). There was significant genomic heterogeneity within each histologic subtype.[43]

There are many targeted agents currently approved by the U.S. Food and Drug Administration (FDA) for a variety of cancers or that are under clinical development and testing. Future investigations into the genomic landscape of ampullary cancer might have significant implications in the selection of appropriate targeted therapies for specific subtypes.

Clinical Presentation and Workup

The workup for patients presenting with clinical suspicion of ampullary neoplasm consists of pancreatic protocol CT (abdomen and pelvis), followed by esophagogastroduodenoscopy (EGD; with a side-viewing endoscope) with or without EUS with biopsy and colonoscopy (if not previously performed). The workup for patients diagnosed with noninvasive ampullary neoplasms, with or without high-grade dysplasia, should be similar to those with periampullary duodenal adenomas.

Endoscopic biopsies of ampullary adenocarcinoma have shown poor diagnostic accuracy, with high false-negative rates reported (~20% to 40%). The presence of adenocarcinoma within an adenoma can be missed by endoscopic biopsies; the final pathologic analyses have at times reported adenocarcinoma foci in what were initially diagnosed as ampullary adenomas.[44-49] EUS and CT are commonly used imaging techniques in the initial diagnosis and subsequent staging of ampullary neoplasms, with EUS noted as the more specific and sensitive modality in several small, single-institution, prospective studies.[50-55]

Version 2.2026 © 2026 National Comprehensive Cancer Network© (NCCN©), All rights reserved. NCCN Guidelines® and this illustration may not be reproduced in any form without the express written permission of NCCN.

PLEASE NOTE that use of this NCCN Content is governed by the End-User License Agreement, and you MAY NOT distribute this Content or use it with any artificial intelligence model or tool.
Printed by Galya Basol Kochav on 2/14/2026 7:41:36 AM. Copyright © 2026 National Comprehensive Cancer Network, Inc. All Rights Reserved.

Ampullary Adenoma

Ampullary adenomas are benign tumors that can arise sporadically or in the setting of hereditary polyposis syndromes such as familial adenomatous polyposis. Ampullary adenomas can potentially undergo malignant transformation and result in ampullary adenocarcinomas; however, the exact course and rate of transformation are still unclear.[56-58]

The Panel recommends that ampullary adenoma be removed endoscopically. However, if endoscopic removal is not possible then pancreatoduodenectomy can be performed. If adenocarcinoma is found in tissue that is excised, the Panel recommends treating adenocarcinomas as described in the next section. Patients with ampullary adenoma and negative margins following endoscopic removal should be endoscopically observed. Patients with positive margins after endoscopic removal can be re-excised or have surgical ampullectomy or pancreatoduodenectomy. Patients with positive margins after ampullectomy can further have pancreatoduodenectomy. Patients who undergo adenoma resection via pancreatoduodenectomy do not need surveillance. All patients undergoing endoscopic removal or surgical ampullectomy should undergo endoscopic surveillance.

There is some debate regarding the optimal management of ampullary adenoma since some cases exhibit foci of occult adenocarcinoma. A few studies have attempted to put forth criteria for endoscopic removal of benign ampullary neoplasms.[59,60] The Panel recommends that ampullary adenomas without suspicion of adenocarcinoma be safely removed endoscopically, including those with high-grade dysplasia. Depending on the size and extent of invasion, ampullary adenomas might require multiple rounds of resection and more than one surgical technique for complete removal.[61-63] All three techniques—endoscopic resection, surgical ampullectomy, and pancreatoduodenectomy—have been shown to be effective in removing ampullary adenomas in retrospective studies.[44,45,48,64-66] In particular, endoscopic resection, also interchangeably referred to as endoscopic papillectomy or endoscopic ampullectomy, has been shown to be effective and safe in patients with ampullary adenomas. The reported recurrence rates are between 6% and 40%, with varying lengths of follow-up with most patients undergoing successful endoscopic resection.[44,60,62,67-71] Commonly reported complications include hemorrhage, perforation, and pancreatitis.[62,67,68,70,72] The Panel recommends that endoscopic removal of ampullary adenomas be performed at high-volume tertiary centers and that ampullectomy be performed at surgical centers with expertise.

Studies directly comparing the three resection techniques are scant and mostly retrospective.[61,63,72] A study (n = 137) comparing all three modalities with surveillance found that endoscopic resection was associated with higher residual and recurrent tumor rates than pancreatoduodenectomy (27.6% vs. 0% and 17.2% vs. 0%, respectively) but fewer adverse events (AEs) (10.2% vs. 29%). This study contained too few surgical ampullectomies (n = 4) to be able to draw any meaningful conclusions.[72] Another study directly comparing endoscopic resection and surgical ampullectomy (n = 109) reported no difference in mortality, margin positivity, and re-excision rates. However, endoscopic resection was significantly associated with lower morbidity (18% vs. 42%; $P = .006$) and readmission rates (16% vs. 34%; $P = .03$).[63] In a study including 180 patients with ampullary adenomas, endoscopic resection was associated with a greater risk of recurrence than operative resection (32% vs. 3%; $P = .006$) but lower rates of complication (58% vs. 29%; $P < .001$).[61] A meta-analysis, which included five studies and a total of 466 patients with ampullary adenomas, concurred that surgical treatment had a lower recurrence rate (risk difference [RD], 0.10; 95% CI, –0.01 to 0.19) than endoscopic resection; however, no difference in complication rates was found (RD, –0.15; 95% CI, –0.53 to 0.23).[73] Overall, endoscopic resection

Version 2.2026 © 2026 National Comprehensive Cancer Network© (NCCN©), All rights reserved. NCCN Guidelines® and this illustration may not be reproduced in any form without the express written permission of NCCN.

PLEASE NOTE that use of this NCCN Content is governed by the End-User License Agreement, and you MAY NOT distribute this Content or use it with any artificial intelligence model or tool.
Printed by Galya Basol Kochav on 2/14/2026 7:41:36 AM. Copyright © 2026 National Comprehensive Cancer Network, Inc. All Rights Reserved.

seems to be associated with more recurrences, but is generally safer than surgical procedures.

Ampullary Adenocarcinoma

Patients presenting with ampullary adenocarcinoma should receive further workup consisting of chest CT, pancreas protocol CT of abdomen/pelvis, liver function tests, and detection of baseline CA 19-9 and carcinoembryonic antigen (CEA). These guidelines derive their pancreatic cancer radiology reporting template from the NCCN Guidelines for Pancreatic Adenocarcinoma (available at www.NCCN.org). Endoscopic retrograde cholangiopancreatography (ERCP)/percutaneous transhepatic cholangiography (PTC) can be considered as clinically indicated. ERCP/PTC has been used frequently in the evaluation of ampullary neoplasms and can provide additional diagnostic capability beyond what EGD/EUS and CT can offer, albeit with increased morbidity and even mortality.[47,52,62,64,74]

If the workup does not show metastatic disease, then patients may undergo MRI evaluation as clinically indicated for indeterminate liver lesions. PET/CT may be used when MRI cannot be performed (eg, pacemaker-dependent patient). If the workup shows metastatic disease, then biopsy confirmation, preferably from a metastatic site, is recommended. Core biopsy is recommended, if possible, to obtain adequate tissue for molecular testing or other ancillary studies. If possible, after primary or metastatic tumor biopsy, histologic subtyping of the tumor as pancreatobiliary, intestinal, or mixed should be performed.

Multidisciplinary consultation is warranted and the expertise review including diagnostic imaging, interventional endoscopy, medical oncology, radiation oncology, surgery, pathology, geriatric medicine, genetic counseling, and palliative care should be considered. A registered dietitian can also be consulted (see NCCN Guidelines for Older Adult Oncology and NCCN Guidelines for Palliative Care; available at www.NCCN.org).

Genetic testing for inherited mutations is recommended for any patient with confirmed ampullary cancer or positive family history of cancer, using comprehensive gene panels for hereditary cancer syndromes. Genetic counseling is recommended for patients who test positive for a pathogenic mutation (*ATM, BRCA1, BRCA2, CDKN2A, MLH1, MSH2*, *MSH6, PALB2, PMS2, STK11,* and *TP53*) or for patients with a positive family history of cancer, regardless of mutation status.

Tumor/somatic molecular profiling, preferably using a next-generation sequencing (NGS) assay, is recommended for patients with metastatic disease who are candidates for anti-cancer therapy to identify clinically actionable and/or emerging alterations, if clinically indicated. These alterations include, but not limited to: fusions (*ALK*, *NRG1*, *NTRK*, *ROS1*, *FGFR2*, and *RET*), mutations (*BRAF*, *BRCA1/2*, *KRAS*, and *PALB2*), amplifications (*HER2*), MSI, dMMR, or TMB using comprehensive genomic profiling via an FDA-approved and/or validated NGS-based assay and *HER2* overexpression via IHC ± FISH. RNA sequencing assays are preferred for detecting RNA fusions, because gene fusions are better detected by RNA-based NGS. Testing on tumor tissue is preferred; however, cell-free DNA testing can be considered if tumor tissue testing is not feasible.

Treatment of Ampullary Adenocarcinoma

Treatment of Localized Disease

The first line of treatment for localized ampullary adenocarcinoma usually involves surgery (preferred), primarily pancreatoduodenectomy. Tissue is obtained to determine the pathologic stage of the tumor, completeness of resection, and other histopathologic features that impact prognosis and clinical management. Decisions about diagnostic management and

Version 2.2026 © 2026 National Comprehensive Cancer Network© (NCCN©), All rights reserved. NCCN Guidelines® and this illustration may not be reproduced in any form without the express written permission of NCCN.

PLEASE NOTE that use of this NCCN Content is governed by the End-User License Agreement, and you MAY NOT distribute this Content or use it with any artificial intelligence model or tool.
Printed by Galya Basol Kochav on 2/14/2026 7:41:36 AM. Copyright © 2026 National Comprehensive Cancer Network, Inc. All Rights Reserved.

resectability should involve multidisciplinary consultation at a high-volume center with reference to appropriate high-quality imaging studies to evaluate the extent of disease. Biliary stent placement is not routinely recommended prior to planned surgery; however, a stent may be considered for symptoms of cholangitis/fever or severe symptomatic jaundice (intense pruritus), or if surgery is being delayed for any reason, including neoadjuvant therapy.

Neoadjuvant systemic therapy with or without subsequent chemoradiation can be considered, particularly in patients with high-risk features. High-risk features include equivocal or indeterminate imaging findings, markedly elevated CA 19-9 and CEA, large primary tumors, large regional lymph nodes, excessive weight loss, and extreme pain. There is limited evidence to recommend specific neoadjuvant regimens off-study, and practices vary with regard to the use of chemotherapy and chemoradiation. After neoadjuvant therapy and stent placement, pancreatic protocol CT or MRI is recommended, followed by surgery in case of resectable disease. Locally advanced disease in the current version is treated similar to metastatic disease.

All resected ampullary cancers can receive adjuvant treatment. The initiation of adjuvant systemic therapy is recommended within 12 weeks of surgery if the patient is medically fit. Patients who have received neoadjuvant chemotherapy or chemoradiation may be candidates for additional chemotherapy (or chemoradiation if none was delivered neoadjuvantly) following surgery and multidisciplinary review. The adjuvant therapy options are dependent on the response to neoadjuvant therapy and other clinical considerations. Total duration of systemic therapy is typically 6 months. The recommendations for each disease stage are as follows: 1) stage I: systemic therapy or observation; 2) stage II: systemic therapy with or without subsequent chemoradiation or observation; and 3) stage III: systemic therapy with or without subsequent chemoradiation. After adjuvant therapy, patients should undergo surveillance every 3 to 6 months for 2 years, then every 6 to 12 months for up to 5 years or as clinically indicated. During surveillance, history and physical examination, chest CT and CT or MRI of the abdomen and pelvis with contrast, and CEA and/or CA 19-9 measurements are recommended.

Surgical Techniques

Pancreatoduodenectomy is the surgical technique for removal of primary ampullary adenocarcinoma, with reported postoperative 5-year survival of 32% to 78%.[4-6,8,11,15,75-78] The reported morbidity and mortality rates for this procedure range from 27% to 59% and 2% to 10%, respectively.[4,5,8,48,66,75-80] It should be noted that most studies are small, retrospective, and combine results for benign with malignant ampullary neoplasms or ampullary cancers with other periampullary cancers. Prognostic factors for survival and recurrence include lymphovascular invasion, perineural invasion, tumor size and stage, ulceration, differentiation, presence and extent of lymph node metastasis, resection margin status, as well as CEA and CA 19-9 levels.[4-6,8,12,66,76,80-83] However, data vary widely across studies on each of these parameters. For example, perineural invasion is not always documented on the pathology report and thus is not included in many analyses. Studies that did include perineural invasion found that association with recurrence and/or survival, at least when univariate analyses was performed.[4,12,82,84,85] Bettschart et al (n = 70) reported a median survival of 18.7 versus 51.9 months for cancers with and without perineural invasion, respectively ($P = .001$).[14] Song et al (n = 89) reported 5-year survival rates of 36.8% versus 72.1% in those with and without perineural invasion, respectively ($P < .001$).[85] Studies have reported contradictory associations of recurrence/survival with CEA or CA 19-9.[8,12,81,82,86] Due to lack of consistent data, the prognostic utility of these markers remains controversial.

Version 2.2026 © 2026 National Comprehensive Cancer Network© (NCCN©), All rights reserved. NCCN Guidelines® and this illustration may not be reproduced in any form without the express written permission of NCCN.

PLEASE NOTE that use of this NCCN Content is governed by the End-User License Agreement, and you MAY NOT distribute this Content or use it with any artificial intelligence model or tool.
Printed by Galya Basol Kochav on 2/14/2026 7:41:36 AM. Copyright © 2026 National Comprehensive Cancer Network, Inc. All Rights Reserved.

The impact of histologic subtype on surgical outcome is, perhaps, even more understudied. Park et al (n = 93) demonstrated that among patients who developed early recurrence (defined as within 6 months of surgery; disease-free survival [DFS] = 4.2 months), the pancreatobiliary subtype recurred early compared to the intestinal subtype (71.4% vs. 28.6% early recurrences; *P* = .001). However, this might be due to a higher number of patients with advanced T stage and lymph node metastases in the pancreatobiliary subtype.[84] Bolm et al reported median OS after pancreatoduodenectomy to be statistically significant between pancreatobiliary/mixed subtype versus intestinal subtype (118 months vs. 156 months; univariate analysis, *P* = .003).[87] Thus far, evidence is not definitive on whether histologic subtypes are independent prognostic factors for outcomes.

Studies have reported lymph node positivity in 30% to 67% of patients with ampullary adenocarcinomas undergoing pancreatoduodenectomy.[6,8,48,66,82,85,88,89] Adequate lymph node assessment may be more challenging after neoadjuvant therapy, but the panel consensus is assessment of at least 12 lymph nodes..[90-92] Survival was significantly better for node-negative versus node-positive disease in several studies, with a couple of exceptions where <100 patients were included.[5,8,48,66,75-77,79,82] A large population-based study that included 1301 patients who underwent resection for ampullary cancer reported significantly higher 5- and 10-year disease-specific survival (DSS) for node-negative versus node-positive disease (59.4% vs. 28.4%; *P* < .001 and 54.1% vs. 21.9%; *P* < .001, respectively).[79] Increased number of positive lymph nodes is associated with diminished survival. In a small study (n = 34), cumulative 5-year survival rates were reported to be 85% with 0 positive nodes, 63% with 1 to 3 positive nodes, and 0% with ≥4 positive nodes (*P* < .0001).[89] Factors such as tumor size, histologic grade, perineural invasion, microscopic vessel invasion, depth of invasion, and morphology have been associated with lymph node invasion.[66,85] A study (n = 450) noted that the risk of lymph node invasion increased with T stage (T1, 28.0%; T2, 50.9%; T3, 71.7%; T4, 77.3%; *P* < .001).[66] Another study (n = 259) reported similar results, with lymph node positivity rates at 11.3%, 28.4%, 43.8%, and 100% for T1, T2, T3, and T4 tumors, respectively.[88]

There are few studies directly comparing pancreatoduodenectomy and surgical ampullectomy. A large study (n = 450; pancreatoduodenectomy = 435, ampullectomy = 15) that included both ampullary adenomas and ampullary adenocarcinomas reported no statistical difference in morbidity (52.2% vs. 33.3%) or mortality (2.1% vs. 0%) between the two procedures.[66] The number of ampullectomies in this study, however, was too small to draw a meaningful conclusion. A smaller study (with 63 pancreatoduodenectomies and 26 ampullectomies) demonstrated that those who underwent pancreatoduodenectomy had more postoperative complications, including significantly higher mean blood loss, longer operative time, and more pancreatic fistula. There were also three deaths with pancreatoduodenectomy versus no deaths with ampullectomy. Patients who had pancreatoduodenectomy tended to present more frequently with jaundice and large tumor size. There was no difference in 5-year OS (65.6% vs. 64.6%), but pancreatoduodenectomy resulted in longer DFS (median months ~85 vs. ~40—; *P* = .025).[85] Overall, ampullectomy seems to result in lower morbidity and mortality, but is associated with a higher recurrence rate.[48] A few studies have attempted to establish standard indications for ampullectomy in patients with ampullary adenocarcinoma; however, the specific criteria remain to be determined.[54,93] Laparoscopic and robotic pancreatoduodenectomies have become more widespread due to their potential for quicker recovery and shorter hospital stays; however, how they compare to open pancreatoduodenectomy remains to be investigated.[15,78,94-97] Meta-analysis and a multicenter international cohort study show that perioperative outcomes including operative time, blood loss, and length of

Version 2.2026 © 2026 National Comprehensive Cancer Network© (NCCN©), All rights reserved. NCCN Guidelines® and this illustration may not be reproduced in any form without the express written permission of NCCN.

PLEASE NOTE that use of this NCCN Content is governed by the End-User License Agreement, and you MAY NOT distribute this Content or use it with any artificial intelligence model or tool.
Printed by Galya Basol Kochav on 2/14/2026 7:41:36 AM. Copyright © 2026 National Comprehensive Cancer Network, Inc. All Rights Reserved.

stay were better with laparoscopic procedures compared to open pancreatoduodenectomies.[98,99]

Postoperatively, the rates of recurrence and time to recurrence vary widely across studies. Recurrences have been reported as early as <6 months and as late as 22.5 months after surgery.[5,12,81,84,88,100] The rates of recurrence range between 28% and 55%, with distant recurrences making up the majority (~80%) in many studies. For distant recurrences, the most common site of metastasis is the liver (38%–65% of distant recurrences).[5,81,84,88,100] Other sites of metastasis are the peritoneum, lung, and bones. One study noted that while pancreatic invasion and tumor size were predictive of locoregional recurrence, lymph node involvement was the sole predictor for liver metastasis.[5]

Neoadjuvant Therapy

Very few studies have investigated neoadjuvant therapy in ampullary cancer. Overall, the use of neoadjuvant therapy is low, varying between 1% and 4% of patients undergoing surgery.[101,102] In the biggest study with a total of 8688 patients with ampullary cancer, 175 of whom received neoadjuvant therapy, no significant difference in OS was observed between the neoadjuvant and the surgery-first groups (43 vs. 33 months, respectively; $P = .416$). In this study patients who received neoadjuvant therapy were more likely to be younger or have nodal metastases.[101] These observations were recapitulated in two other studies.[102,103] Despite no significant improvements in survival, neoadjuvant therapy led to downstaging (15%–67% of tumors) and was associated with decreased adjuvant chemotherapy or chemoradiation use.[102-104] These studies emphasize the need for careful selection of patients who might benefit from neoadjuvant therapy.

Neoadjuvant therapy options for pancreatobiliary/mixed-type ampullary cancer include albumin-bound paclitaxel/gemcitabine, capecitabine/gemcitabine, cisplatin/gemcitabine, and FOLFIRINOX (5-FU//irinotecan/leucovorin/oxaliplatin) or modified FOLFIRINOX (mFOLFIRINOX). Chemoradiation after neoadjuvant therapy is an option based on multidisciplinary tumor board discussions. The recommendations for FOLFIRINOX or mFOLFIRINOX, albumin-bound paclitaxel/gemcitabine, and cisplatin/gemcitabine are derived from the NCCN Guidelines for Pancreatic Adenocarcinoma and NCCN Guidelines for Biliary Tract Cancers (available at www.NCCN.org). Based on their clinical expertise, the Panel added capecitabine/gemcitabine for pancreatobiliary/mixed type ampullary cancer. The Panel notes that there are no prospective randomized phase III data supporting these recommendations. The available evidence is derived from prospective or randomized phase II studies and retrospective data.[105-110] For more information on these studies, see the Discussion sections of the NCCN Guidelines for Pancreatic Adenocarcinoma and the NCCN Guidelines for Biliary Tract Cancers (available at www.NCCN.org).

Neoadjuvant therapy options for intestinal type ampullary cancer include CapeOx (capecitabine/oxaliplatin), FOLFIRINOX, and FOLFOX (5-FU/ /leucovorin/oxaliplatin). All of these regimens can be potentially followed by chemoradiation based on multidisciplinary tumor board discussion. These regimens are derived based on recommendations from the NCCN Guidelines for Colon Cancer and the NCCN Guidelines for Small Bowel Adenocarcinoma (available at www.NCCN.org), which are based on high-level evidence, phase III randomized data from the neoadjuvant FOxTROT trial (FOLFOX, CapeOx) in localized colon cancer, TRIBE and TRIBE2 trials (FOLFOXIRI) for metastatic disease, and a phase II study with neoadjuvant FOLFOXIRI for localized colon cancer.[111-113] For more information on these studies, see the Discussion section of the NCCN Guidelines for Colon Cancer (available at www.NCCN.org).

Version 2.2026 © 2026 National Comprehensive Cancer Network© (NCCN©), All rights reserved. NCCN Guidelines® and this illustration may not be reproduced in any form without the express written permission of NCCN.

PLEASE NOTE that use of this NCCN Content is governed by the End-User License Agreement, and you MAY NOT distribute this Content or use it with any artificial intelligence model or tool.
Printed by Galya Basol Kochav on 2/14/2026 7:41:36 AM. Copyright © 2026 National Comprehensive Cancer Network, Inc. All Rights Reserved.

Adjuvant Therapy

Adjuvant therapy is frequently utilized after curative resection in ampullary cancer, most often in the form of chemotherapy. Radiotherapy can also be used in the adjuvant setting, often in combination with chemotherapy.[114] The Panel recommends that adjuvant systemic therapy can be initiated within 12 weeks of surgery based on the patient factors. Following surgery and a multidisciplinary review, patients who have received neoadjuvant chemoradiation or chemotherapy may be candidates for additional chemotherapy based on regimens administered neoadjuvantly. The Panel notes that chemotherapy should be given prior to the administration of chemoradiation, if chemoradiation is being considered due to positive or close margins. Most adjuvant therapy studies in ampullary adenocarcinoma are retrospective in nature. In a large analysis of National Cancer Database (NCDB) data (n = 4190), both adjuvant chemotherapy (n = 880) and adjuvant chemoradiation (n = 670) were associated with improved OS compared to observation (n = 2640). In an initial analysis, median OS in the adjuvant chemotherapy group and the observation group were 47.2 and 35.5 months, respectively (hazard ratio [HR], 0.82; $P < .01$). In the second analysis, median OS in the adjuvant chemoradiation group and the observation group were 38.1 months and 31.0 months, respectively (HR, 0.84; $P = .02$). Disease with high-risk features, such as higher T and N stages, seemed to benefit from both adjuvant chemotherapy and chemoradiation.[115] Two large meta-analyses studies (n = 71 studies and 8280 patients and n = 10 studies and 3361 patients), along with many smaller retrospective studies, show that adjuvant therapy, whether chemotherapy, radiotherapy, or chemoradiation, is clinically beneficial for resected ampullary cancers.[26,86,87,104,116-118] Certain studies specifically document the usefulness of adjuvant therapy for patients with lymph node involvement.[114,117,119] Narang et al (n = 186) demonstrated that in patients with lymph node involvement, adjuvant chemoradiation was associated with longer OS (median OS, 32.1 vs. 15.7 months; HR, 0.47; $P = .004$) compared to observation. In this study, adjuvant therapy was more likely used for higher T stage, lymph node involvement, and close or positive margins.[114] Kamarajah et al (n = 1106) showed that adjuvant radiotherapy for N2 disease improved both DSS (median, 27 vs. 19 months; $P = .0044$) and OS (median, 23 vs. 17 months; $P = .0091$).[117] Interestingly, Bolm et al (n = 214) reported that adjuvant therapy (gemcitabine, gemcitabine + oxaliplatin, capecitabine, FOLFOX, chemoradiation, or unknown regimen) was beneficial for the pancreatobiliary subtype (improved median OS, 85 vs. 65 months for observation; $P = .005$) but not the intestinal subtype.[87]

Despite several reports showing the benefit of adjuvant therapy, there also exist studies demonstrating that adjuvant therapy has no effect on recurrence and survival outcomes.[5,9,120-126] In these studies, adjuvant therapy was more frequently used in patients with more advanced disease (poorly differentiated, higher T/N stage). In a retrospective study (n = 475), no OS or relapse-free survival (RFS) benefit was noted with adjuvant 5-FU + leucovorin-based chemotherapy compared to observation, even after stratification by TNM stage. The intestinal subtype, but not the pancreatobiliary/mixed subtype, seemed to benefit from adjuvant therapy compared to observation (5-year OS, 83.7% vs. 33.2%; $P = .015$; and RFS 46.5% vs. 24.9%; $P = .035$).[122] Another study showed that adjuvant chemoradiation (5-FU plus 50.4 Gy) slightly improved survival for patients with cancers with perineural invasion versus observation (30.4 vs. 12.5 months; $P = .08$).[66]

Adjuvant therapy options for pancreatobiliary/mixed subtype include 5-FU/leucovorin (category 1), gemcitabine (category 1), capecitabine, capecitabine/gemcitabine, cisplatin/gemcitabine, FOLFOX or CapeOx, and mFOLFIRINOX. Based on the same data, the Panel recommends 5-FU/leucovorin (category 1), capecitabine, and FOLFOX or CapeOx as adjuvant therapy options for intestinal subtype.

Version 2.2026 © 2026 National Comprehensive Cancer Network© (NCCN©), All rights reserved. NCCN Guidelines® and this illustration may not be reproduced in any form without the express written permission of NCCN.

PLEASE NOTE that use of this NCCN Content is governed by the End-User License Agreement, and you MAY NOT distribute this Content or use it with any artificial intelligence model or tool.
Printed by Galya Basol Kochav on 2/14/2026 7:41:36 AM. Copyright © 2026 National Comprehensive Cancer Network, Inc. All Rights Reserved.

The recommendations for 5-FU/leucovorin and gemcitabine are based on results of the ESPAC-3 trial.[27] In this phase III, randomized, open-label trial, patients with ampullary, bile duct, or other periampullary cancers were randomized to 5-FU/leucovorin (n = 100), gemcitabine (n = 92), or observation (n = 105). The median survival for each arm was 57.8, 70.8, and 40.6 months, respectively. Statistical comparisons between treatment arms were not reported for individual cancer types. When data for all 3 cancer types were combined, there was no significant difference in survival between treatment arms, but the HR for chemotherapy compared to observation was significant ($P = .03$). The rate of treatment-related serious AEs was higher in those receiving 5-FU/leucovorin than in those receiving gemcitabine (49% vs. 30%; $P = .002$). Based on the high level of evidence presented in this study, the Panel assigned a category 1 designation to 5-FU/leucovorin and gemcitabine for the adjuvant treatment of resected ampullary adenocarcinoma. The recommendation for gemcitabine is also based on data from CONKO-001 investigating adjuvant therapy in pancreatic cancer.[127]

The recommendation for capecitabine/gemcitabine is based on extrapolation of data from ESPAC-4.[128] ESPAC-4, a phase III, randomized, open-label trial, tested gemcitabine monotherapy or capecitabine/gemcitabine as adjuvant treatment for resected pancreatic cancer. A total of 730 patients were included in the final analysis, 366 in the gemcitabine arm and 364 in the capecitabine/gemcitabine arm. The median OS was 25.5 months and 28 months in the gemcitabine and gemcitabine + capecitabine arm, respectively ($P = .032$). While 54% of patients in the monotherapy group experienced any grade 3–4 AEs, this rate was 63% in the combination arm.

The recommendation for cisplatin/gemcitabine is extrapolated from a phase II randomized trial that enrolled 410 patients with advanced biliary tract cancer.[129] Ampullary cancers were included, but the exact number was not reported. Patients with locally advanced or metastatic disease were randomly assigned to receive either cisplatin/gemcitabine (n = 204) or gemcitabine monotherapy (n = 206). The median OS and median progression-free survival (PFS) were significantly longer in the combination group versus the monotherapy group: OS, 11.7 vs. 8.1 months; $P < .001$ and PFS, 8.0 vs. 5.0 months; $P < .001$, respectively. The rates of any grade 3–4 AEs were similar between the 2 arms (70.7% vs. 68.8% for combination and single agent, respectively). Cisplatin/gemcitabine was not tested in the adjuvant setting in this trial, but other smaller trials tested adjuvant cisplatin/gemcitabine after surgery for biliary cancers.[130,131]

The recommendation for CapeOx is extrapolated from a phase II trial that enrolled a total of 31 patients with advanced small bowel and ampullary cancers, 12 of whom had ampullary cancer.[132] All patients had metastatic or unresectable tumors and had not received prior systemic chemotherapy. All patients in this trial received CapeOx. The overall response rate was 50%, and the median OS was 20.4 months. CapeOx was not tested in the adjuvant setting in this trial. The Panel deems FOLFOX a reasonable alternative to CapeOx based on clinical experience with these agents in periampullary cancers. In addition, the recommendation of FOLFOX or CapeOx adjuvant therapy for intestinal type ampullary cancers is also derived from trials testing these agents in colon cancer.[133,134]

The recommendation for capecitabine is based on extrapolation of data from BILCAP, a phase III randomized trial that enrolled 447 patients with biliary tract cancer (cholangiocarcinoma or muscle-invasive gallbladder cancer).[135] In this study, patients were randomly assigned to capecitabine (n = 223) or observation (n = 224) after surgery. After a median follow-up of 60 months, the median OS was statistically similar between the two arms (51.1 vs. 36.4 months in the capecitabine vs. observation groups,

Version 2.2026 © 2026 National Comprehensive Cancer Network© (NCCN©), All rights reserved. NCCN Guidelines® and this illustration may not be reproduced in any form without the express written permission of NCCN.

PLEASE NOTE that use of this NCCN Content is governed by the End-User License Agreement, and you MAY NOT distribute this Content or use it with any artificial intelligence model or tool.
Printed by Galya Basol Kochav on 2/14/2026 7:41:36 AM. Copyright © 2026 National Comprehensive Cancer Network, Inc. All Rights Reserved.

respectively; *P* = .097). Serious AEs were observed in 21% of patients in the capecitabine group and 10% of patients in the observation group. The recommendation for capecitabine adjuvant therapy for intestinal type ampullary adenocarcinoma is derived from the X-ACT study in colon cancer.[136]

The recommendation for mFOLFIRINOX is based on extrapolation of data from the phase III PRODIGE 24/CCTG PA.6 randomized trial in resected pancreatic cancer.[137] Patients (n = 493) with pancreatic cancer were randomly assigned postoperatively to receive mFOLFIRINOX (n = 247) or gemcitabine (n = 246). The median PFS and median OS were significantly longer in the mFOLFIRINOX group compared to the gemcitabine group (21.6 vs. 12.8 months; *P* < .001; and 54.4 vs. 35.0 months; *P* = .003, respectively). The rate of grade 3–4 AEs was higher in the mFOLFIRINOX group (75.9% vs. 52.9%).

Chemoradiation

The Panel recommendations for chemoradiation in ampullary adenocarcinoma are similar to those in the NCCN Guidelines for Pancreatic Adenocarcinoma, NCCN Guidelines for Biliary Tract Cancers, and NCCN Guidelines for Small Bowel Adenocarcinoma (available at www.NCCN.org). Capecitabine + concurrent RT and 5-FU + concurrent RT are options for pancreatobiliary, mixed, and intestinal types, while gemcitabine + concurrent RT is recommended for pancreatobiliary type only. All three regimens have been investigated in the adjuvant setting in small, retrospective, and single-institutional studies.[26,86,104,114,115,118,126] 5-FU–based chemoradiation regimens were commonly used in these studies. An analysis of data from NCDB in which patients received adjuvant chemotherapy (n = 870) or adjuvant chemoradiation (n = 669) revealed that adjuvant chemotherapy use increased (9%–32% between 2004–2005 and 2012–2013) during the same time that adjuvant chemoradiation use decreased (20%–12%).[115] Contradictory studies exist with respect to the usefulness of adjuvant chemoradiation in patients with ampullary cancer.[86,104,114,115,126] A systematic review and meta-analysis of 10 retrospective studies, including 3361 patients with ampullary cancer, looked at adjuvant RT delivered with concurrent chemotherapy (mostly 5-FU). Adjuvant chemoradiation significantly reduced the risk of death (HR, 0.75; *P* = .01).[118] Several studies show that adjuvant chemoradiation particularly benefits patients who have node-positive disease.[114,118,119] A phase III, randomized EORTC trial tested adjuvant chemoradiation with 5-FU versus observation after surgery in patients with pancreatic head and periampullary cancers. Of the 103 patients assigned to the observation arm, 57 had pancreatic cancer, 44 had periampullary cancer, and 2 were unknown; of the 104 patients assigned to the treatment arm, 55 had pancreatic cancer, 48 had periampullary cancer, and 1 was unknown. The number of patients with ampullary cancer was not reported in this study. The final analysis showed no significant difference in median or 2-year survival rates between the two arms.[138] There is more high-level evidence on chemoradiation in the setting of pancreatic cancer, such as data from ESPAC-1, which can be extrapolated to ampullary cancer.[139] For more information on these studies, see the Discussion section of the NCCN Guidelines for Pancreatic Adenocarcinoma (available at www.NCCN.org).

Treatment of Metastatic Disease

Patients diagnosed with metastatic ampullary adenocarcinomas should obtain genetic testing for hereditary mutations and molecular profiling of tumor tissue, if not previously done. Chemoradiation may be used for palliative indications. For select patients with oligometastatic disease and response/stable disease to systemic therapy, local-directed therapy to liver or lung metastases may be considered after multidisciplinary tumor board review. Patients with poor performance status (PS) should also receive palliative and best supportive care or palliative RT.

Version 2.2026 © 2026 National Comprehensive Cancer Network© (NCCN©), All rights reserved. NCCN Guidelines® and this illustration may not be reproduced in any form without the express written permission of NCCN.

PLEASE NOTE that use of this NCCN Content is governed by the End-User License Agreement, and you MAY NOT distribute this Content or use it with any artificial intelligence model or tool.
Printed by Galya Basol Kochav on 2/14/2026 7:41:36 AM. Copyright © 2026 National Comprehensive Cancer Network, Inc. All Rights Reserved.

First-Line Systemic Therapy

For pancreatobiliary/mixed type ampullary cancer with good and intermediate PS, the Panel included albumin-bound paclitaxel/gemcitabine, capecitabine/gemcitabine, cisplatin/gemcitabine, cisplatin/durvalumab/gemcitabine, and FOLFOX. For good PS 0–1 only the Panel also recommends FOLFIRINOX/mFOLFIRINOX, and NALIRIFOX (5-FU/liposomal irinotecan/leucovorin/oxaliplatin). The recommendations for these regimens are derived from the NCCN Guidelines for Pancreatic Adenocarcinoma and the NCCN Guidelines for Biliary Tract Cancers (available at www.NCCN.org), with the Panel adding FOLFOX based on their clinical experience. These recommendations are mostly based on phase II/III randomized data for albumin-bound paclitaxel/gemcitabine,[140] capecitabine/gemcitabine,[141] cisplatin/gemcitabine,[129] cisplatin/durvalumab/gemcitabine,[142] and FOLFIRINOX/mFOLFIRINOX.[143,144] For more information on these studies, see the Discussion section of the NCCN Guidelines for Pancreatic Adenocarcinoma and NCCN Guidelines for Biliary Tract Cancers (available at www.NCCN.org). For pancreatobiliary/mixed type ampullary cancer with poor PS, simplified formulations of certain regimens can be utilized; however, providing palliative and best supportive care are preferred.

For intestinal type ampullary cancer, all recommendations are derived from the NCCN Guidelines for Colon Cancer (available at www.NCCN.org). Most of the recommendations are based on phase II/III, randomized data for CapeOx ± bevacizumab,[145] FOLFIRI (5-FU//irinotecan/leucovorin) ± bevacizumab,[146] FOLFIRINOX ± bevacizumab,[147] and FOLFOX ± bevacizumab.[145,148] While all of these options are appropriate for patients with good and intermediate PS, 5-FU + leucovorin and capecitabine are considered appropriate options for those with intermediate PS, with the same rationale of reducing toxicity.[148-150] For poor PS, the systemic therapy options include capecitabine and 5-FU/leucovorin. For more information on these studies, see the Discussion section of the NCCN Guidelines for Colon Cancer (available at www.NCCN.org). Due to the controversial role and scant available data for anti-EGFR therapies in *KRAS* wild-type small bowel cancers or for right-sided colon cancers, the Panel does not recommend using anti-EGFR therapies for *KRAS* wild-type ampullary adenocarcinomas of intestinal subtype.

In addition to chemotherapy recommendations, pembrolizumab is a recommended option for all ampullary adenocarcinomas with MSI-H, dMMR, or TMB-H (≥10 mut/Mb), and ipilimumab + nivolumab is a recommended option for MSI-H, dMMR intestinal type ampullary adenocarcinomas. However, due to higher toxicity of the nivolumab plus ipilumumab combination, nivolumab monotherapy is recommended for patients with poor PS. Patients can also receive entrectinib or larotrectinib or repotrectinib if the tumors test positive for *NTRK* gene fusion. Selpercatinib is also recommended for tumors with *RET* fusion positivity. These options are applicable regardless of PS. With the exception of ipilimumab + nivolumab, the rationale for which comes from the metastatic colorectal cancer setting, the other regimens are supported by basket trials that include many different cancer types. No ampullary cancer or a very small number of periampullary cancers were included in these studies. Therefore, cautious extrapolation of data from these studies to the ampullary cancer setting is prudent.

The recommendation for pembrolizumab is supported by data from the phase II KEYNOTE-518 study, in which a total of 233 patients representing 27 tumor types were treated with pembrolizumab after disease progression with prior therapy.[151] The objective response rate was 34.3%, median PFS was 4.1 months, and median OS was 23.5 months. The rate of grade 3–5 treatment-related AEs was 14.6%. No patient with ampullary cancer was enrolled in this trial.

Version 2.2026 © 2026 National Comprehensive Cancer Network© (NCCN©), All rights reserved. NCCN Guidelines® and this illustration may not be reproduced in any form without the express written permission of NCCN.

PLEASE NOTE that use of this NCCN Content is governed by the End-User License Agreement, and you MAY NOT distribute this Content or use it with any artificial intelligence model or tool.
Printed by Galya Basol Kochav on 2/14/2026 7:41:36 AM. Copyright © 2026 National Comprehensive Cancer Network, Inc. All Rights Reserved.

The recommendation for ipilimumab + nivolumab is based on data in the metastatic colorectal cancer setting, hence its suitability only for intestinal type ampullary cancer.[152] In the phase II CheckMate 142 study, patients with no prior treatment received ipilimumab + nivolumab until disease progression. The objective response rate was 69%, while 2-year PFS and 2-year OS were 74% and 79%, respectively. The rate of grade 3–4 treatment-related AEs was 22%. This trial also included a cohort of previously treated patients. In this group (n = 119), the objective response rate was 55% and the 1-year PFS and 1-year OS were 71% and 85%, respectively. The rate of grade 3–4 treatment-related AEs was 32%.[153]

The recommendations for larotrectinib and entrectinib are supported by data from two phase I–II basket trials.[154,155] The first enrolled 55 patients, including 4 with colon cancer, 2 with cholangiocarcinoma, and 1 with pancreatic cancer, who were treated with larotrectinib. The overall response rate was 75%, and neither the median duration of response nor the median PFS was reached after a median follow-up of 9.9 months.[154] The second basket trial enrolled 54 patients, including 4 with colorectal cancer, 3 with pancreatic cancer, and 1 with cholangiocarcinoma. Objective response was noted in 57% of patients and the median PFS and median OS were 11 months and 21 months, respectively.[155] Patients in both of these trials had received prior systemic therapy. The FDA issued accelerated approval for repotrectinib, another *NTRK*-based regimen, for adult and pediatric patients ≥12 years with solid tumors that have *NTRK* gene fusions, are locally advanced or metastatic or where surgical resection is likely to result in severe morbidity, and that have progressed following standard treatment or have no satisfactory alternative therapy. A small number of patients with pancreatic adenocarcinoma were evaluated in the TRIDENT trial; however no ampullary cancers were included.[156]

Selpercatinib, a kinase inhibitor, received accelerated approval from the FDA based on treatment of *RET* fusion-positive non-small cell lung cancer, medullary thyroid, and thyroid cancers. The recommendations are based on the trial that included 11 patients with pancreatic adenocarcinoma, at least 50% of whom had objective response rates.[157]

Based on the FDA approvals, dabrafenib + trametinib can be used as a treatment option for *BRAF* V600E-mutated ampullary adenocarcinomas, regardless of PS. NCI-MATCH Subprotocol H, an open-label study that evaluated dabrafenib + trametinib in patients with solid tumors, lymphomas, or multiple myeloma whose tumors harbored a *BRAF* V600E mutation, the response rate was 37.9% (n = 29), with a median duration of response of 25.1 months. With a median follow-up of 23 months, median OS was 28.6 months and median PFS was 11.4 months.[158] ROAR, a phase II, open-label basket trial in patients with *BRAF* V600E-mutated rare cancers showed that in 43 patients with *BRAF* V600E-mutated biliary tract cancer, the response rate was 47% (by independent reviewer). Median OS was 14 months and median PFS was 9 months.[159]

Treatment for Disease Progression

Patients with disease progression and good/intermediate PS should preferably be enrolled in clinical trials. Alternative options are systemic chemotherapy, or possibly targeted therapy based on molecular profiling as clinically indicated, or palliative RT for severe pain refractory to analgesic therapy. Patients with disease progression and poor PS should receive palliative and best supportive care and be considered for systemic therapy, targeted therapy based on molecular profiling as clinically indicated, or palliative RT. For specific systemic therapy regimen recommendations, see *Principles of Systemic Therapy* in the algorithm. For anyone receiving therapy for disease progression, serial imaging is recommended as indicated to assess disease response.

Systemic Therapy Options

In case of disease progression, the rule of thumb is that any regimen other than the one used in the first-line setting is a possible option. In patients

Version 2.2026 © 2026 National Comprehensive Cancer Network© (NCCN©), All rights reserved. NCCN Guidelines® and this illustration may not be reproduced in any form without the express written permission of NCCN.

PLEASE NOTE that use of this NCCN Content is governed by the End-User License Agreement, and you MAY NOT distribute this Content or use it with any artificial intelligence model or tool.
Printed by Galya Basol Kochav on 2/14/2026 7:41:36 AM. Copyright © 2026 National Comprehensive Cancer Network, Inc. All Rights Reserved.

with good/intermediate PS and pancreatobiliary/mixed type ampullary cancer previously treated with a gemcitabine-based regimen, a fluoropyrimidine-based regimen is recommended for subsequent-line therapy. Capecitabine,[160] CapeOx,[161] 5-FU/leucovorin,[127,162,163] 5-FU/leucovorin/liposomal irinotecan,[162,164,165] FOLFIRI,[166-169] FOLFIRINOX[170] or mFOLFIRINOX and FOLFOX,[171-175] and OFF (5-FU/leucovorin/oxaliplatin)[163,176] are recommended options. Conversely, in patients with good/intermediate PS and pancreatobiliary/mixed type ampullary cancer previously treated with a fluoropyrimidine-based regimen, a gemcitabine-based regimen is recommended for subsequent-line therapy. Albumin-bound paclitaxel/gemcitabine, capecitabine/gemcitabine, and gemcitabine can be used. In addition, FOLFIRI[166,167] or 5-FU/leucovorin/liposomal irinotecan[162] can be tried in case of no progression on prior irinotecan or oxaliplatin. In patients with poor PS and pancreatobiliary/mixed type ampullary cancer, gemcitabine,[160] capecitabine,[160] or 5-FU/leucovorin[162,163] can be used. Some of these regimens have been added based on the Panel's clinical expertise.

In addition to these agents, cisplatin/gemcitabine for known *BRCA1/2/PALB2* mutations is recommended for patients with good/intermediate PS. This recommendation is supported by data from a phase II randomized trial where 50 patients with previously untreated pancreatic cancer with germline *BRCA/PALB2* mutations were randomly assigned to cisplatin/gemcitabine or cisplatin/gemcitabine/veliparib. The response rate was 74.1% and 65.2% for each arm, respectively; median PFS was 10.1 months and 9.7 months, and median OS was 15.5 months and 16.4 months, respectively.[177]

Similar to recommendations for the first-line setting, all of the recommendations for the subsequent-line setting are derived from phase II/III data in pancreatic cancer or biliary cancer, with the exception of the reference for FOLFIRINOX, which is an exploratory analysis of the MPACT trial.[170] For more information on these studies, see the Discussion sections of the NCCN Guidelines for Pancreatic Adenocarcinoma and NCCN Guidelines for Biliary Tract Cancers (available at www.NCCN.org).

For patients with good PS and intestinal type ampullary cancer, FOLFIRI ± bevacizumab is a possible subsequent-line option for patients previously treated with an oxaliplatin-based regimen. Capecitabine ± bevacizumab, CapeOx ± bevacizumab,[145] 5-FU/leucovorin ± bevacizumab, or FOLFOX ± bevacizumab[145,148] can be used for patients with intermediate PS and previously treated with an irinotecan-based regimen. For patients with poor PS and intestinal type ampullary cancer, palliative/best supportive care are preferred; however, capecitabine or 5-FU/Leucovorin are also options. Similar to recommendations for the first-line setting, all of the recommendations for the subsequent-line setting are derived from phase II/III data in colon cancer. For more information on these studies, see the Discussion section of the NCCN Guidelines for Colon Cancer (available at www.NCCN.org).

Targeted therapy regimens recommended in the first-line setting are also possible options for disease progression. They are similar to recommendations for metastatic disease (see algorithm for specific regimens). Trials demonstrating the efficacy of these regimens included all or a portion of patients who had received and progressed on prior systemic therapy.[151,153-155,157-159]

Furthermore, dostarlimab-gxly is recommended for patients with any PS in tumors with MSI-H or dMMR. This recommendation is based on results of a phase I basket study where a total of 209 patients, including 99 with gastrointestinal cancer (69 with colorectal cancer), received dostarlimab-gxly until disease progression or discontinuation. The objective response rate was 41.6%.[178]

Version 2.2026 © 2026 National Comprehensive Cancer Network© (NCCN©), All rights reserved. NCCN Guidelines® and this illustration may not be reproduced in any form without the express written permission of NCCN.

PLEASE NOTE that use of this NCCN Content is governed by the End-User License Agreement, and you MAY NOT distribute this Content or use it with any artificial intelligence model or tool.
Printed by Galya Basol Kochav on 2/14/2026 7:41:36 AM. Copyright © 2026 National Comprehensive Cancer Network, Inc. All Rights Reserved.

Additionally, HER2 overexpression occurs in 13% of ampullary cancers, and HER2 targeting is relevant. In 2024, the FDA granted accelerated approval to fam-trastuzumab deruxtecan-nxki for adult patients with unresectable or metastatic HER2-positive (IHC3+) solid tumors who have received prior systemic treatment and have no satisfactory alternative treatment options. The DESTINY-PanTumor2 trial included a total of 25 patients (all with good PS) with advanced or metastatic pancreatic cancer, with <20% of patients having tumors that expressed IHC 3+ HER2.[179] In this trial, 16 patients with BTCs with HER IHC3+ expression, the investigator-assessed ORR, median OS, and median PFS were 56.3%, 12.4 months, and 7.4 months, respectively. The median OS and PFS were 7.1 months (95% CI, 4.7%–14.6%), 5.1 months (95% CI, 3.0%–7.3%), respectively in 22 evaluable patients with HER2-positive advanced BTCs in the HERB trial.[180] In patients with advanced colon cancer and HER2 expression (IHC 3+ or IHC 2+/ISH+) the primary endpoint of ORR was 45.3%, with one complete response and 23 partial responses.[181] Given the similarity between ampullary adenocarcinoma and biliary tract tumors along with intestinal subtypes addressed in these guidelines, the Panel recommends fam-trastuzumab as a subsequent therapy option only for patients with good PS and HER2 IHC 3+ expression.

Palliative and Best Supportive Care

The recommendations for palliative and best supportive care are the same as those for pancreatic adenocarcinoma (see Discussion section in the NCCN Guidelines for Pancreatic Adenocarcinoma, available at www.NCCN.org).

Summary

In summary, these guidelines discuss primary treatment for ampullary adenomas and adenocarcinomas, which consist of appropriate surgical, RT, and systemic therapy options including neoadjuvant, adjuvant, and subsequent lines of therapy.

Version 2.2026 © 2026 National Comprehensive Cancer Network© (NCCN©), All rights reserved. NCCN Guidelines® and this illustration may not be reproduced in any form without the express written permission of NCCN.

PLEASE NOTE that use of this NCCN Content is governed by the End-User License Agreement, and you MAY NOT distribute this Content or use it with any artificial intelligence model or tool.
Printed by Galya Basol Kochav on 2/14/2026 7:41:36 AM. Copyright © 2026 National Comprehensive Cancer Network, Inc. All Rights Reserved.

References

1. Ahn DH, Bekaii-Saab T. Ampullary cancer: an overview. Am Soc Clin Oncol Educ Book 2014:112–115. Available at: https://www.ncbi.nlm.nih.gov/pubmed/24857067.

2. Westgaard A, Tafjord S, Farstad IN, et al. Pancreatobiliary versus intestinal histologic type of differentiation is an independent prognostic factor in resected periampullary adenocarcinoma. BMC Cancer 2008;8:170. Available at: https://www.ncbi.nlm.nih.gov/pubmed/18547417.

3. Ramai D, Ofosu A, Singh J, et al. Demographics, tumor characteristics, treatment, and clinical outcomes of patients with ampullary cancer: a Surveillance, Epidemiology, and End Results (SEER) cohort study. Minerva Gastroenterol Dietol 2019;65:85–90. Available at: https://www.ncbi.nlm.nih.gov/pubmed/30488680.

4. Balachandran P, Sikora SS, Kapoor S, et al. Long-term survival and recurrence patterns in ampullary cancer. Pancreas 2006;32:390–395. Available at: https://www.ncbi.nlm.nih.gov/pubmed/16670621.

5. Hsu HP, Yang TM, Hsieh YH, et al. Predictors for patterns of failure after pancreaticoduodenectomy in ampullary cancer. Ann Surg Oncol 2007;14:50–60. Available at: https://www.ncbi.nlm.nih.gov/pubmed/17054003.

6. Sommerville CA, Limongelli P, Pai M, et al. Survival analysis after pancreatic resection for ampullary and pancreatic head carcinoma: an analysis of clinicopathological factors. J Surg Oncol 2009;100:651–656. Available at: https://www.ncbi.nlm.nih.gov/pubmed/19722229.

7. Lemke J, Schafer D, Sander S, et al. Survival and prognostic factors in pancreatic and ampullary cancer. Anticancer Res 2014;34:3011–3020. Available at: https://www.ncbi.nlm.nih.gov/pubmed/24922667.

8. Klein F, Jacob D, Bahra M, et al. Prognostic factors for long-term survival in patients with ampullary carcinoma: the results of a 15-year observation period after pancreaticoduodenectomy. HPB Surg 2014;2014:970234. Available at: https://www.ncbi.nlm.nih.gov/pubmed/24723741.

9. Showalter TN, Zhan T, Anne PR, et al. The influence of prognostic factors and adjuvant chemoradiation on survival after pancreaticoduodenectomy for ampullary carcinoma. J Gastrointest Surg 2011;15:1411–1416. Available at: https://www.ncbi.nlm.nih.gov/pubmed/21523621.

10. He J, Ahuja N, Makary MA, et al. 2564 resected periampullary adenocarcinomas at a single institution: trends over three decades. HPB (Oxford) 2014;16:83–90. Available at: https://www.ncbi.nlm.nih.gov/pubmed/23472829.

11. Chen SC, Shyr YM, Wang SE. Longterm survival after pancreaticoduodenectomy for periampullary adenocarcinomas. HPB (Oxford) 2013;15:951–957. Available at: https://www.ncbi.nlm.nih.gov/pubmed/23472708.

12. Woo SM, Ryu JK, Lee SH, et al. Recurrence and prognostic factors of ampullary carcinoma after radical resection: comparison with distal extrahepatic cholangiocarcinoma. Ann Surg Oncol 2007;14:3195–3201. Available at: https://www.ncbi.nlm.nih.gov/pubmed/17710498.

13. Williams JL, Chan CK, Toste PA, et al. Association of histopathologic phenotype of periampullary adenocarcinomas with survival. JAMA Surg 2017;152:82–88. Available at: https://www.ncbi.nlm.nih.gov/pubmed/27732711.

14. Bettschart V, Rahman MQ, Engelken FJ, et al. Presentation, treatment and outcome in patients with ampullary tumours. Br J Surg 2004;91:1600–1607. Available at: https://www.ncbi.nlm.nih.gov/pubmed/15515106.

15. Song KB, Kim SC, Lee W, et al. Laparoscopic pancreaticoduodenectomy for periampullary tumors: lessons learned from 500 consecutive patients in a single center. Surg Endosc 2020;34:1343–1352. Available at: https://www.ncbi.nlm.nih.gov/pubmed/31214805.

Version 2.2026 © 2026 National Comprehensive Cancer Network© (NCCN©), All rights reserved. NCCN Guidelines® and this illustration may not be reproduced in any form without the express written permission of NCCN.

PLEASE NOTE that use of this NCCN Content is governed by the End-User License Agreement, and you MAY NOT distribute this Content or use it with any artificial intelligence model or tool.
Printed by Galya Basol Kochav on 2/14/2026 7:41:36 AM. Copyright © 2026 National Comprehensive Cancer Network, Inc. All Rights Reserved.

16. Leo JM, Kalloger SE, Peixoto RD, et al. Immunophenotyping of ampullary carcinomata allows for stratification of treatment specific subgroups. J Clin Pathol 2016;69:431–439. Available at: https://www.ncbi.nlm.nih.gov/pubmed/26500334.

17. Pomianowska E, Grzyb K, Westgaard A, et al. Reclassification of tumour origin in resected periampullary adenocarcinomas reveals underestimation of distal bile duct cancer. Eur J Surg Oncol 2012;38:1043–1050. Available at: https://www.ncbi.nlm.nih.gov/pubmed/22883964.

18. Kimura W, Futakawa N, Yamagata S, et al. Different clinicopathologic findings in two histologic types of carcinoma of papilla of Vater. Jpn J Cancer Res 1994;85:161–166. Available at: https://www.ncbi.nlm.nih.gov/pubmed/7511574.

19. Schueneman A, Goggins M, Ensor J, et al. Validation of histomolecular classification utilizing histological subtype, MUC1, and CDX2 for prognostication of resected ampullary adenocarcinoma. Br J Cancer 2015;113:64–68. Available at: https://www.ncbi.nlm.nih.gov/pubmed/25989273.

20. Chang DK, Jamieson NB, Johns AL, et al. Histomolecular phenotypes and outcome in adenocarcinoma of the ampulla of vater. J Clin Oncol 2013;31:1348–1356. Available at: https://www.ncbi.nlm.nih.gov/pubmed/23439753.

21. Kawabata Y, Tanaka T, Nishisaka T, et al. Cytokeratin 20 (CK20) and apomucin 1 (MUC1) expression in ampullary carcinoma: Correlation with tumor progression and prognosis. Diagn Pathol 2010;5:75. Available at: https://www.ncbi.nlm.nih.gov/pubmed/21106111.

22. Kumari N, Prabha K, Singh RK, et al. Intestinal and pancreatobiliary differentiation in periampullary carcinoma: the role of immunohistochemistry. Hum Pathol 2013;44:2213–2219. Available at: https://www.ncbi.nlm.nih.gov/pubmed/23834763.

23. Ang DC, Shia J, Tang LH, et al. The utility of immunohistochemistry in subtyping adenocarcinoma of the ampulla of vater. Am J Surg Pathol 2014;38:1371–1379. Available at: https://www.ncbi.nlm.nih.gov/pubmed/24832159.

24. Reid MD, Balci S, Ohike N, et al. Ampullary carcinoma is often of mixed or hybrid histologic type: an analysis of reproducibility and clinical relevance of classification as pancreatobiliary versus intestinal in 232 cases. Mod Pathol 2016;29:1575–1585. Available at: https://www.ncbi.nlm.nih.gov/pubmed/27586202.

25. Schiergens TS, Reu S, Neumann J, et al. Histomorphologic and molecular phenotypes predict gemcitabine response and overall survival in adenocarcinoma of the ampulla of Vater. Surgery 2015;158:151–161. Available at: https://www.ncbi.nlm.nih.gov/pubmed/25819575.

26. Zhou YM, Liao S, Wei YZ, Wang SJ. Prognostic factors and benefits of adjuvant therapy for ampullary cancer following pancreatoduodenectomy: A systematic review and meta-analysis. Asian J Surg 2020;43:1133–1141. Available at: https://www.ncbi.nlm.nih.gov/pubmed/32249101.

27. Neoptolemos JP, Moore MJ, Cox TF, et al. Effect of adjuvant chemotherapy with fluorouracil plus folinic acid or gemcitabine vs observation on survival in patients with resected periampullary adenocarcinoma: the ESPAC-3 periampullary cancer randomized trial. JAMA 2012;308:147–156. Available at: https://www.ncbi.nlm.nih.gov/pubmed/22782416.

28. Loehrer PJ, Sr., Feng Y, Cardenes H, et al. Gemcitabine alone versus gemcitabine plus radiotherapy in patients with locally advanced pancreatic cancer: an Eastern Cooperative Oncology Group trial. J Clin Oncol 2011;29:4105–4112. Available at: http://www.ncbi.nlm.nih.gov/pubmed/21969502.

29. Hammel P, Huguet F, van Laethem JL, et al. Effect of chemoradiotherapy vs chemotherapy on survival in patients with locally advanced pancreatic cancer controlled after 4 months of gemcitabine with or without erlotinib: the LAP07 randomized clinical trial. JAMA 2016;315:1844–1853. Available at: https://www.ncbi.nlm.nih.gov/pubmed/27139057.

Version 2.2026 © 2026 National Comprehensive Cancer Network© (NCCN©), All rights reserved. NCCN Guidelines® and this illustration may not be reproduced in any form without the express written permission of NCCN.

PLEASE NOTE that use of this NCCN Content is governed by the End-User License Agreement, and you MAY NOT distribute this Content or use it with any artificial intelligence model or tool.
Printed by Galya Basol Kochav on 2/14/2026 7:41:36 AM. Copyright © 2026 National Comprehensive Cancer Network, Inc. All Rights Reserved.

30. Marinova M, Feradova H, Gonzalez-Carmona MA, et al. Improving quality of life in pancreatic cancer patients following high-intensity focused ultrasound (HIFU) in two European centers. Eur Radiol 2021;31:5818–5829. Available at: https://www.ncbi.nlm.nih.gov/pubmed/33486605.

31. Freedman-Cass DA, Fischer T, Alpert AB, et al. The Value and Process of Inclusion: Using Sensitive, Respectful, and Inclusive Language and Images in NCCN Content. J Natl Compr Canc Netw 2023;21:434–441. Available at: https://www.ncbi.nlm.nih.gov/pubmed/37156485.

32. Valsangkar NP, Ingkakul T, Correa-Gallego C, et al. Survival in ampullary cancer: potential role of different KRAS mutations. Surgery 2015;157:260–268. Available at: https://www.ncbi.nlm.nih.gov/pubmed/25616942.

33. Kwon MJ, Kim JW, Jung JP, et al. Low incidence of KRAS, BRAF, and PIK3CA mutations in adenocarcinomas of the ampulla of Vater and their prognostic value. Hum Pathol 2016;50:90–100. Available at: https://www.ncbi.nlm.nih.gov/pubmed/26997442.

34. Jun SY, Kim M, Jin Gu M, et al. Clinicopathologic and prognostic associations of KRAS and BRAF mutations in small intestinal adenocarcinoma. Mod Pathol 2016;29:402–415. Available at: https://www.ncbi.nlm.nih.gov/pubmed/26892442.

35. Kinugasa H, Kanzaki H, Tanaka T, et al. The impact of KRAS mutation in patients with sporadic nonampullary duodenal epithelial tumors. Clin Transl Gastroenterol 2021;12:e00424. Available at: https://www.ncbi.nlm.nih.gov/pubmed/34797780.

36. Cox AD, Fesik SW, Kimmelman AC, et al. Drugging the undruggable RAS: Mission possible? Nat Rev Drug Discov 2014;13:828–851. Available at: https://www.ncbi.nlm.nih.gov/pubmed/25323927.

37. Achille A, Scupoli MT, Magalini AR, et al. APC gene mutations and allelic losses in sporadic ampullary tumours: evidence of genetic difference from tumours associated with familial adenomatous polyposis. Int J Cancer 1996;68:305–312. Available at: https://www.ncbi.nlm.nih.gov/pubmed/8903471.

38. Harthimmer MR, Stolborg U, Pfeiffer P, et al. Mutational profiling and immunohistochemical analysis of a surgical series of ampullary carcinomas. J Clin Pathol 2019;72:762–770. Available at: https://www.ncbi.nlm.nih.gov/pubmed/31256008.

39. Wong W, Lowery MA, Berger MF, et al. Ampullary cancer: Evaluation of somatic and germline genetic alterations and association with clinical outcomes. Cancer 2019;125:1441–1448. Available at: https://www.ncbi.nlm.nih.gov/pubmed/30620386.

40. Hechtman JF, Liu W, Sadowska J, et al. Sequencing of 279 cancer genes in ampullary carcinoma reveals trends relating to histologic subtypes and frequent amplification and overexpression of ERBB2 (HER2). Mod Pathol 2015;28:1123–1129. Available at: https://www.ncbi.nlm.nih.gov/pubmed/25975284.

41. Kumari N, Singh RK, Mishra SK, et al. Identification of PI3K-AKT signaling as the dominant altered pathway in intestinal type ampullary cancers through whole-exome sequencing. J Pathol Transl Med 2021;55:192–201. Available at: https://www.ncbi.nlm.nih.gov/pubmed/33677956.

42. Kumari N, Singh RK, Mishra SK, et al. Prevalence and spectrum of pathogenic germline variants in intestinal and pancreatobiliary type of ampullary cancer. Pathol Res Pract 2021;217:153309. Available at: https://www.ncbi.nlm.nih.gov/pubmed/33341547.

43. Chakraborty S, Ecker BL, Seier K, et al. Genome-derived classification signature for ampullary adenocarcinoma to improve clinical cancer care. Clin Cancer Res 2021;27:5891–5899. Available at: https://www.ncbi.nlm.nih.gov/pubmed/34433650.

44. Kim HN, Kim KM, Shin JU, et al. Prediction of carcinoma after resection in subjects with ampullary adenomas on endoscopic biopsy. J Clin Gastroenterol 2013;47:346–351. Available at: https://www.ncbi.nlm.nih.gov/pubmed/23442830.

45. Grobmyer SR, Stasik CN, Draganov P, et al. Contemporary results with ampullectomy for 29 "benign" neoplasms of the ampulla. J Am Coll

Version 2.2026 © 2026 National Comprehensive Cancer Network© (NCCN©), All rights reserved. NCCN Guidelines® and this illustration may not be reproduced in any form without the express written permission of NCCN.

PLEASE NOTE that use of this NCCN Content is governed by the End-User License Agreement, and you MAY NOT distribute this Content or use it with any artificial intelligence model or tool.
Printed by Galya Basol Kochav on 2/14/2026 7:41:36 AM. Copyright © 2026 National Comprehensive Cancer Network, Inc. All Rights Reserved.

Surg 2008;206:466–471. Available at: https://www.ncbi.nlm.nih.gov/pubmed/18308217.

46. Elek G, Gyori S, Toth B, Pap A. Histological evaluation of preoperative biopsies from ampulla vateri. Pathol Oncol Res 2003;9:32–41. Available at: https://www.ncbi.nlm.nih.gov/pubmed/12704445.

47. Rodriguez C, Borda F, Elizalde I, et al. How accurate is preoperative diagnosis by endoscopic biopsies in ampullary tumours? Rev Esp Enferm Dig 2002;94:585–592. Available at: https://www.ncbi.nlm.nih.gov/pubmed/12647408.

48. Beger HG, Treitschke F, Gansauge F, et al. Tumor of the ampulla of Vater: experience with local or radical resection in 171 consecutively treated patients. Arch Surg 1999;134:526–532. Available at: https://www.ncbi.nlm.nih.gov/pubmed/10323425.

49. Bellizzi AM, Kahaleh M, Stelow EB. The assessment of specimens procured by endoscopic ampullectomy. Am J Clin Pathol 2009;132:506–513. Available at: https://www.ncbi.nlm.nih.gov/pubmed/19762527.

50. Artifon EL, Couto D, Jr., Sakai P, da Silveira EB. Prospective evaluation of EUS versus CT scan for staging of ampullary cancer. Gastrointest Endosc 2009;70:290–296. Available at: https://www.ncbi.nlm.nih.gov/pubmed/19523619.

51. Okano N, Igarashi Y, Hara S, et al. Endosonographic preoperative evaluation for tumors of the ampulla of vater using endoscopic ultrasonography and intraductal ultrasonography. Clin Endosc 2014;47:174–177. Available at: https://www.ncbi.nlm.nih.gov/pubmed/24765600.

52. Chen WX, Xie QG, Zhang WF, et al. Multiple imaging techniques in the diagnosis of ampullary carcinoma. Hepatobiliary Pancreat Dis Int 2008;7:649–653. Available at: https://www.ncbi.nlm.nih.gov/pubmed/19073413.

53. Ito K, Fujita N, Noda Y, et al. Preoperative evaluation of ampullary neoplasm with EUS and transpapillary intraductal US: a prospective and histopathologically controlled study. Gastrointest Endosc 2007;66:740–747. Available at: https://www.ncbi.nlm.nih.gov/pubmed/17905017.

54. Tien YW, Yeh CC, Wang SP, et al. Is blind pancreaticoduodenectomy justified for patients with ampullary neoplasms? J Gastrointest Surg 2009;13:1666–1673. Available at: https://www.ncbi.nlm.nih.gov/pubmed/19557483.

55. Cannon ME, Carpenter SL, Elta GH, et al. EUS compared with CT, magnetic resonance imaging, and angiography and the influence of biliary stenting on staging accuracy of ampullary neoplasms. Gastrointest Endosc 1999;50:27–33. Available at: https://www.ncbi.nlm.nih.gov/pubmed/10385718.

56. Burke CA, Beck GJ, Church JM, van Stolk RU. The natural history of untreated duodenal and ampullary adenomas in patients with familial adenomatous polyposis followed in an endoscopic surveillance program. Gastrointest Endosc 1999;49:358–364. Available at: https://www.ncbi.nlm.nih.gov/pubmed/10049420.

57. Stolte M, Pscherer C. Adenoma-carcinoma sequence in the papilla of Vater. Scand J Gastroenterol 1996;31:376–382. Available at: https://www.ncbi.nlm.nih.gov/pubmed/8726307.

58. Wen KW, Kim GE, Rabinovitch PS, et al. Diagnosis, risk stratification, and management of ampullary dysplasia by DNA flow cytometric analysis of paraffin-embedded tissue. Mod Pathol 2019;32:1291–1302. Available at: https://www.ncbi.nlm.nih.gov/pubmed/30976103.

59. Cheng CL, Sherman S, Fogel EL, et al. Endoscopic snare papillectomy for tumors of the duodenal papillae. Gastrointest Endosc 2004;60:757–764. Available at: https://www.ncbi.nlm.nih.gov/pubmed/15557951.

60. Bohnacker S, Seitz U, Nguyen D, et al. Endoscopic resection of benign tumors of the duodenal papilla without and with intraductal growth. Gastrointest Endosc 2005;62:551–560. Available at: https://www.ncbi.nlm.nih.gov/pubmed/16185970.

Version 2.2026 © 2026 National Comprehensive Cancer Network© (NCCN©), All rights reserved. NCCN Guidelines® and this illustration may not be reproduced in any form without the express written permission of NCCN.

PLEASE NOTE that use of this NCCN Content is governed by the End-User License Agreement, and you MAY NOT distribute this Content or use it with any artificial intelligence model or tool.
Printed by Galya Basol Kochav on 2/14/2026 7:41:36 AM. Copyright © 2026 National Comprehensive Cancer Network, Inc. All Rights Reserved.

61. Onkendi EO, Naik ND, Rosedahl JK, et al. Adenomas of the ampulla of Vater: a comparison of outcomes of operative and endoscopic resections. J Gastrointest Surg 2014;18:1588–1596. Available at: https://www.ncbi.nlm.nih.gov/pubmed/24916584.

62. Alali A, Espino A, Moris M, et al. Endoscopic resection of ampullary tumours: Long-term outcomes and adverse events. J Can Assoc Gastroenterol 2020;3:17–25. Available at: https://www.ncbi.nlm.nih.gov/pubmed/32010876.

63. Ceppa EP, Burbridge RA, Rialon KL, et al. Endoscopic versus surgical ampullectomy: an algorithm to treat disease of the ampulla of Vater. Ann Surg 2013;257:315–322. Available at: https://www.ncbi.nlm.nih.gov/pubmed/23059497.

64. Kang SH, Kim KH, Kim TN, et al. Therapeutic outcomes of endoscopic papillectomy for ampullary neoplasms: retrospective analysis of a multicenter study. BMC Gastroenterol 2017;17:69. Available at: https://www.ncbi.nlm.nih.gov/pubmed/28558658.

65. Clary BM, Tyler DS, Dematos P, et al. Local ampullary resection with careful intraoperative frozen section evaluation for presumed benign ampullary neoplasms. Surgery 2000;127:628–633. Available at: https://www.ncbi.nlm.nih.gov/pubmed/10840357.

66. Winter JM, Cameron JL, Olino K, et al. Clinicopathologic analysis of ampullary neoplasms in 450 patients: Implications for surgical strategy and long-term prognosis. J Gastrointest Surg 2010;14:379–387. Available at: https://doi.org/10.1007/s11605-009-1080-7.

67. van der Wiel SE, Poley JW, Koch AD, Bruno MJ. Endoscopic resection of advanced ampullary adenomas: a single-center 14-year retrospective cohort study. Surg Endosc 2019;33:1180–1188. Available at: https://www.ncbi.nlm.nih.gov/pubmed/30167949.

68. Napoleon B, Gincul R, Ponchon T, et al. Endoscopic papillectomy for early ampullary tumors: long-term results from a large multicenter prospective study. Endoscopy 2014;46:127–134. Available at: https://www.ncbi.nlm.nih.gov/pubmed/24477368.

69. Ridtitid W, Tan D, Schmidt SE, et al. Endoscopic papillectomy: risk factors for incomplete resection and recurrence during long-term follow-up. Gastrointest Endosc 2014;79:289–296. Available at: https://www.ncbi.nlm.nih.gov/pubmed/24094466.

70. Catalano MF, Linder JD, Chak A, et al. Endoscopic management of adenoma of the major duodenal papilla. Gastrointest Endosc 2004;59:225–232. Available at: https://www.ncbi.nlm.nih.gov/pubmed/14745396.

71. Irani S, Arai A, Ayub K, et al. Papillectomy for ampullary neoplasm: results of a single referral center over a 10-year period. Gastrointest Endosc 2009;70:923–932. Available at: https://www.ncbi.nlm.nih.gov/pubmed/19608181.

72. Angsuwatcharakon P, Ahmed O, Lynch PM, et al. Management of ampullary adenomas in familial adenomatous polyposis syndrome: 16 years of experience from a tertiary cancer center. Gastrointest Endosc 2020;92:323–330. Available at: https://www.ncbi.nlm.nih.gov/pubmed/32145286.

73. Mendonca EQ, Bernardo WM, Moura EG, et al. Endoscopic versus surgical treatment of ampullary adenomas: a systematic review and meta-analysis. Clinics (Sao Paulo) 2016;71:28–35. Available at: https://www.ncbi.nlm.nih.gov/pubmed/26872081.

74. Ridtitid W, Schmidt SE, Al-Haddad MA, et al. Performance characteristics of EUS for locoregional evaluation of ampullary lesions. Gastrointest Endosc 2015;81:380–388. Available at: https://www.ncbi.nlm.nih.gov/pubmed/25293823.

75. Di Giorgio A, Alfieri S, Rotondi F, et al. Pancreatoduodenectomy for tumors of Vater's ampulla: report on 94 consecutive patients. World J Surg 2005;29:513–518. Available at: https://www.ncbi.nlm.nih.gov/pubmed/15776300.

76. Duffy JP, Hines OJ, Liu JH, et al. Improved survival for adenocarcinoma of the ampulla of Vater: fifty-five consecutive resections.

Version 2.2026 © 2026 National Comprehensive Cancer Network© (NCCN©), All rights reserved. NCCN Guidelines® and this illustration may not be reproduced in any form without the express written permission of NCCN.

PLEASE NOTE that use of this NCCN Content is governed by the End-User License Agreement, and you MAY NOT distribute this Content or use it with any artificial intelligence model or tool.
Printed by Galya Basol Kochav on 2/14/2026 7:41:36 AM. Copyright © 2026 National Comprehensive Cancer Network, Inc. All Rights Reserved.

Arch Surg 2003;138:941–948; discussion 948–950. Available at: https://www.ncbi.nlm.nih.gov/pubmed/12963649.

77. Brown KM, Tompkins AJ, Yong S, et al. Pancreaticoduodenectomy is curative in the majority of patients with node-negative ampullary cancer. Arch Surg 2005;140:529–532; discussion 532–523. Available at: https://www.ncbi.nlm.nih.gov/pubmed/15967899.

78. Dembinski J, Yoh T, Aussilhou B, et al. The long-term outcomes of laparoscopic versus open pancreatoduodenectomy for ampullary carcinoma showed similar survival: a case-matched comparative study. Surg Endosc 2022;36:4732–4740. Available at: https://www.ncbi.nlm.nih.gov/pubmed/34724575.

79. O'Connell JB, Maggard MA, Manunga J, Jr., et al. Survival after resection of ampullary carcinoma: a national population-based study. Ann Surg Oncol 2008;15:1820–1827. Available at: https://www.ncbi.nlm.nih.gov/pubmed/18369675.

80. Qiao QL, Zhao YG, Ye ML, et al. Carcinoma of the ampulla of Vater: factors influencing long-term survival of 127 patients with resection. World J Surg 2007;31:137–143; discussion 144–136. Available at: https://www.ncbi.nlm.nih.gov/pubmed/17171495.

81. Todoroki T, Koike N, Morishita Y, et al. Patterns and predictors of failure after curative resections of carcinoma of the ampulla of Vater. Ann Surg Oncol 2003;10:1176–1183. Available at: https://www.ncbi.nlm.nih.gov/pubmed/14654474.

82. Lazaryan A, Kalmadi S, Almhanna K, et al. Predictors of clinical outcomes of resected ampullary adenocarcinoma: a single-institution experience. Eur J Surg Oncol 2011;37:791–797. Available at: https://www.ncbi.nlm.nih.gov/pubmed/21741199.

83. Allema JH, Reinders ME, van Gulik TM, et al. Results of pancreaticoduodenectomy for ampullary carcinoma and analysis of prognostic factors for survival. Surgery 1995;117:247–253. Available at: https://www.ncbi.nlm.nih.gov/pubmed/7878528.

84. Park HM, Park SJ, Han SS, et al. Very early recurrence following pancreaticoduodenectomy in patients with ampullary cancer. Medicine (Baltimore) 2019;98:e17711. Available at: https://www.ncbi.nlm.nih.gov/pubmed/31689805.

85. Song J, Liu H, Li Z, et al. Long-term prognosis of surgical treatment for early ampullary cancers and implications for local ampullectomy. BMC Surg 2015;15:32. Available at: https://www.ncbi.nlm.nih.gov/pubmed/25888004.

86. Ha HR, Oh DY, Kim TY, et al. Survival outcomes according to adjuvant treatment and prognostic factors including host immune markers in patients with curatively resected ampulla of Vater cancer. PLoS One 2016;11:e0151406. Available at: https://www.ncbi.nlm.nih.gov/pubmed/26974670.

87. Bolm L, Ohrner K, Nappo G, et al. Adjuvant therapy is associated with improved overall survival in patients with pancreatobiliary or mixed subtype ampullary cancer after pancreatoduodenectomy - A multicenter cohort study. Pancreatology 2020;20:433–441. Available at: https://www.ncbi.nlm.nih.gov/pubmed/31987649.

88. Kim H, Kwon W, Kim JR, et al. Recurrence patterns after pancreaticoduodenectomy for ampullary cancer. J Hepatobiliary Pancreat Sci 2019;26:179–186. Available at: https://www.ncbi.nlm.nih.gov/pubmed/30849209.

89. Sakata J, Shirai Y, Wakai T, et al. Assessment of the nodal status in ampullary carcinoma: the number of positive lymph nodes versus the lymph node ratio. World J Surg 2011;35:2118–2124. Available at: https://www.ncbi.nlm.nih.gov/pubmed/21717240.

90. Nassour I, Christie A, Choti MA, et al. Determining the adequate examined lymph node count in resected ampullary adenocarcinoma-A national cohort study. J Gastrointest Surg 2018;22:792–801. Available at: https://www.ncbi.nlm.nih.gov/pubmed/29546687.

91. Balci S, Basturk O, Saka B, et al. Substaging nodal status in ampullary carcinomas has significant prognostic value: Proposed revised staging

Version 2.2026 © 2026 National Comprehensive Cancer Network© (NCCN©), All rights reserved. NCCN Guidelines® and this illustration may not be reproduced in any form without the express written permission of NCCN.

PLEASE NOTE that use of this NCCN Content is governed by the End-User License Agreement, and you MAY NOT distribute this Content or use it with any artificial intelligence model or tool.
Printed by Galya Basol Kochav on 2/14/2026 7:41:36 AM. Copyright © 2026 National Comprehensive Cancer Network, Inc. All Rights Reserved.

based on an analysis of 313 well-characterized cases. Ann Surg Oncol 2015;22:4392–4401. Available at: https://www.ncbi.nlm.nih.gov/pubmed/25783680.

92. Partelli S, Crippa S, Capelli P, et al. Adequacy of lymph node retrieval for ampullary cancer and its association with improved staging and survival. World J Surg 2013;37:1397–1404. Available at: https://www.ncbi.nlm.nih.gov/pubmed/23546531.

93. Rattner DW, Fernandez-del Castillo C, Brugge WR, Warshaw AL. Defining the criteria for local resection of ampullary neoplasms. Arch Surg 1996;131:366–371. Available at: https://www.ncbi.nlm.nih.gov/pubmed/8615720.

94. Palanivelu C, Senthilnathan P, Sabnis SC, et al. Randomized clinical trial of laparoscopic versus open pancreatoduodenectomy for periampullary tumours. Br J Surg 2017;104:1443–1450. Available at: https://www.ncbi.nlm.nih.gov/pubmed/28895142.

95. Senthilnathan P, Srivatsan Gurumurthy S, Gul SI, et al. Long-term results of laparoscopic pancreaticoduodenectomy for pancreatic and periampullary cancer-experience of 130 cases from a tertiary-care center in South India. J Laparoendosc Adv Surg Tech A 2015;25:295–300. Available at: https://www.ncbi.nlm.nih.gov/pubmed/25789541.

96. Nassour I, Wang SC, Christie A, et al. Minimally invasive versus open pancreaticoduodenectomy: A propensity-matched study from a national cohort of patients. Ann Surg 2018;268:151–157. Available at: https://www.ncbi.nlm.nih.gov/pubmed/28486387.

97. Zureikat AH, Beane JD, Zenati MS, et al. 500 minimally invasive robotic pancreatoduodenectomies: One decade of optimizing performance. Ann Surg 2021;273:966–972. Available at: https://www.ncbi.nlm.nih.gov/pubmed/31851003.

98. Reis PCA, Bittar V, Almiron G, et al. Laparoscopic Versus Open Pancreatoduodenectomy for Periampullary Tumors: A Systematic Review and Meta-Analysis of Randomized Controlled Trials. J Gastrointest Cancer 2024;55:1058–1068. Available at: https://www.ncbi.nlm.nih.gov/pubmed/39028397.

99. Uijterwijk BA, Moekotte A, Boggi U, et al. Oncological resection and perioperative outcomes of robotic, laparoscopic and open pancreatoduodenectomy for ampullary adenocarcinoma: a propensity score matched international multicenter cohort study. HPB (Oxford) 2025;27:318–329. Available at: https://www.ncbi.nlm.nih.gov/pubmed/39765373.

100. Park JS, Yoon DS, Kim KS, et al. Factors influencing recurrence after curative resection for ampulla of Vater carcinoma. J Surg Oncol 2007;95:286–290. Available at: https://www.ncbi.nlm.nih.gov/pubmed/17326125.

101. Guo M, Beal EW, Miller ED, et al. Neoadjuvant therapy versus surgery first for ampullary carcinoma: A propensity score-matched analysis of the NCDB. J Surg Oncol 2021;123:1558–1567. Available at: https://www.ncbi.nlm.nih.gov/pubmed/33596343.

102. Adam MA, Glencer A, AlMasri S, et al. Neoadjuvant therapy versus upfront resection for nonpancreatic periampullary adenocarcinoma. Ann Surg Oncol 2022. Available at: https://www.ncbi.nlm.nih.gov/pubmed/35925536.

103. Cloyd JM, Wang H, Overman M, et al. Influence of preoperative therapy on short- and long-term outcomes of patients with adenocarcinoma of the ampulla of Vater. Ann Surg Oncol 2017;24:2031–2039. Available at: https://www.ncbi.nlm.nih.gov/pubmed/28124275.

104. Palta M, Patel P, Broadwater G, et al. Carcinoma of the ampulla of Vater: patterns of failure following resection and benefit of chemoradiotherapy. Ann Surg Oncol 2012;19:1535–1540. Available at: https://www.ncbi.nlm.nih.gov/pubmed/22045467.

105. Varadhachary GR, Wolff RA, Crane CH, et al. Preoperative gemcitabine and cisplatin followed by gemcitabine-based chemoradiation for resectable adenocarcinoma of the pancreatic head. J Clin Oncol

Version 2.2026 © 2026 National Comprehensive Cancer Network© (NCCN©), All rights reserved. NCCN Guidelines® and this illustration may not be reproduced in any form without the express written permission of NCCN.

PLEASE NOTE that use of this NCCN Content is governed by the End-User License Agreement, and you MAY NOT distribute this Content or use it with any artificial intelligence model or tool.
Printed by Galya Basol Kochav on 2/14/2026 7:41:36 AM. Copyright © 2026 National Comprehensive Cancer Network, Inc. All Rights Reserved.

2008;26:3487–3495. Available at: https://www.ncbi.nlm.nih.gov/pubmed/18640929.

106. Palmer DH, Stocken DD, Hewitt H, et al. A randomized phase 2 trial of neoadjuvant chemotherapy in resectable pancreatic cancer: gemcitabine alone versus gemcitabine combined with cisplatin. Ann Surg Oncol 2007;14:2088–2096. Available at: https://www.ncbi.nlm.nih.gov/pubmed/17453298.

107. Evans DB, Varadhachary GR, Crane CH, et al. Preoperative gemcitabine-based chemoradiation for patients with resectable adenocarcinoma of the pancreatic head. J Clin Oncol 2008;26:3496–3502. Available at: https://www.ncbi.nlm.nih.gov/pubmed/18640930.

108. Ettrich TJ, Uhl W, Kornmann M, et al. Perioperative or adjuvant nab-paclitaxel plus gemcitabine for resectable pancreatic cancer: Updated final results of the randomized phase II AIO-NEONAX trial. Journal of Clinical Oncology 2022;40:4133–4133. Available at: https://ascopubs.org/doi/abs/10.1200/JCO.2022.40.16_suppl.4133.

109. Sohal DPS, Duong M, Ahmad SA, et al. Efficacy of perioperative chemotherapy for resectable pancreatic adenocarcinoma: A phase 2 randomized clinical trial. JAMA Oncol 2021;7:421–427. Available at: https://www.ncbi.nlm.nih.gov/pubmed/33475684.

110. Katz MHG, Shi Q, Meyers J, et al. Efficacy of preoperative mFOLFIRINOX vs mFOLFIRINOX plus hypofractionated radiotherapy for borderline resectable adenocarcinoma of the pancreas: The A021501 phase 2 randomized clinical trial. JAMA Oncol 2022;8:1263–1270. Available at: https://www.ncbi.nlm.nih.gov/pubmed/35834226.

111. Cremolini C, Antoniotti C, Rossini D, et al. Upfront FOLFOXIRI plus bevacizumab and reintroduction after progression versus mFOLFOX6 plus bevacizumab followed by FOLFIRI plus bevacizumab in the treatment of patients with metastatic colorectal cancer (TRIBE2): a multicentre, open-label, phase 3, randomised, controlled trial. Lancet Oncol 2020;21:497–507. Available at: https://www.ncbi.nlm.nih.gov/pubmed/32164906.

112. Cremolini C, Loupakis F, Antoniotti C, et al. FOLFOXIRI plus bevacizumab versus FOLFIRI plus bevacizumab as first-line treatment of patients with metastatic colorectal cancer: updated overall survival and molecular subgroup analyses of the open-label, phase 3 TRIBE study. Lancet Oncol 2015;16:1306–1315. Available at: https://www.ncbi.nlm.nih.gov/pubmed/26338525.

113. Seymour MT, Morton D, Investigators obotIFT. FOxTROT: an international randomised controlled trial in 1052 patients (pts) evaluating neoadjuvant chemotherapy (NAC) for colon cancer. J Clin Oncol 2019;37:3504–3504. Available at: https://ascopubs.org/doi/abs/10.1200/JCO.2019.37.15_suppl.3504.

114. Narang AK, Miller RC, Hsu CC, et al. Evaluation of adjuvant chemoradiation therapy for ampullary adenocarcinoma: the Johns Hopkins Hospital-Mayo Clinic collaborative study. Radiat Oncol 2011;6:126. Available at: https://www.ncbi.nlm.nih.gov/pubmed/21951377.

115. Nassour I, Hynan LS, Christie A, et al. Association of adjuvant therapy with improved survival in ampullary cancer: A national cohort study. J Gastrointest Surg 2018;22:695–702. Available at: https://www.ncbi.nlm.nih.gov/pubmed/29127604.

116. Jin Z, Hartgers ML, Sanhueza CT, et al. Prognostic factors and benefits of adjuvant therapy after pancreatoduodenectomy for ampullary adenocarcinoma: Mayo Clinic experience. Eur J Surg Oncol 2018;44:677–683. Available at: https://www.ncbi.nlm.nih.gov/pubmed/29506768.

117. Kamarajah SK. Adjuvant radiotherapy following pancreaticoduodenectomy for ampullary adenocarcinoma improves survival in node-positive patients: a propensity score analysis. Clin Transl Oncol 2018;20:1212–1218. Available at: https://www.ncbi.nlm.nih.gov/pubmed/29497964.

118. Kwon J, Kim BH, Kim K, et al. Survival benefit of adjuvant chemoradiotherapy in patients with ampulla of Vater cancer: A systematic review and meta-analysis. Ann Surg 2015;262:47–52. Available at: https://www.ncbi.nlm.nih.gov/pubmed/25775067.

Version 2.2026 © 2026 National Comprehensive Cancer Network© (NCCN©), All rights reserved. NCCN Guidelines® and this illustration may not be reproduced in any form without the express written permission of NCCN.

PLEASE NOTE that use of this NCCN Content is governed by the End-User License Agreement, and you MAY NOT distribute this Content or use it with any artificial intelligence model or tool.
Printed by Galya Basol Kochav on 2/14/2026 7:41:36 AM. Copyright © 2026 National Comprehensive Cancer Network, Inc. All Rights Reserved.

119. Bhatia S, Miller RC, Haddock MG, et al. Adjuvant therapy for ampullary carcinomas: the Mayo Clinic experience. Int J Radiat Oncol Biol Phys 2006;66:514–519. Available at: https://www.ncbi.nlm.nih.gov/pubmed/16863684.

120. Chavez MT, Sharpe JP, O'Brien T, et al. Management and outcomes following pancreaticoduodenectomy for ampullary adenocarcinoma. Am J Surg 2017;214:856–861. Available at: https://www.ncbi.nlm.nih.gov/pubmed/28285709.

121. Sikora SS, Balachandran P, Dimri K, et al. Adjuvant chemo-radiotherapy in ampullary cancers. Eur J Surg Oncol 2005;31:158–163. Available at: https://www.ncbi.nlm.nih.gov/pubmed/15698732.

122. Kang J, Lee W, Shin J, et al. Controversial benefit of 5-fluorouracil/leucovorin-based adjuvant chemotherapy for ampullary cancer: a propensity score-matched analysis. Langenbecks Arch Surg 2022;407:1091–1097. Available at: https://www.ncbi.nlm.nih.gov/pubmed/35013798.

123. Al-Jumayli M, Batool A, Middiniti A, et al. Clinical outcome of ampullary carcinoma: Single cancer center experience. J Oncol 2019;2019:3293509. Available at: https://www.ncbi.nlm.nih.gov/pubmed/31186632.

124. Krishnan S, Rana V, Evans DB, et al. Role of adjuvant chemoradiation therapy in adenocarcinomas of the ampulla of vater. Int J Radiat Oncol Biol Phys 2008;70:735–743. Available at: https://www.ncbi.nlm.nih.gov/pubmed/17980502.

125. Manne A, Hatic H, Li P, et al. The clinical benefit of adjuvant therapy in long-term survival of early-stage ampullary carcinoma: A single institutional experience. J Clin Med Res 2020;12:560–567. Available at: https://www.ncbi.nlm.nih.gov/pubmed/32849944.

126. Zhou J, Hsu CC, Winter JM, et al. Adjuvant chemoradiation versus surgery alone for adenocarcinoma of the ampulla of Vater. Radiother Oncol 2009;92:244–248. Available at: https://www.ncbi.nlm.nih.gov/pubmed/19541379.

127. Oettle H, Neuhaus P, Hochhaus A, et al. Adjuvant chemotherapy with gemcitabine and long-term outcomes among patients with resected pancreatic cancer: the CONKO-001 randomized trial. JAMA 2013;310:1473–1481. Available at: http://www.ncbi.nlm.nih.gov/pubmed/24104372.

128. Neoptolemos JP, Palmer DH, Ghaneh P, et al. Comparison of adjuvant gemcitabine and capecitabine with gemcitabine monotherapy in patients with resected pancreatic cancer (ESPAC-4): a multicentre, open-label, randomised, phase 3 trial. Lancet 2017;389:1011–1024. Available at: https://www.ncbi.nlm.nih.gov/pubmed/28129987.

129. Valle J, Wasan H, Palmer DH, et al. Cisplatin plus gemcitabine versus gemcitabine for biliary tract cancer. N Engl J Med 2010;362:1273–1281. Available at: https://www.ncbi.nlm.nih.gov/pubmed/20375404.

130. Mori S, Aoki T, Shiraki T, et al. Efficacy and feasibility of adjuvant gemcitabine plus cisplatin chemotherapy after major hepatectomy for biliary tract cancer. Anticancer Res 2021;41:5231–5240. Available at: https://www.ncbi.nlm.nih.gov/pubmed/34593476.

131. Siebenhuner AR, Seifert H, Bachmann H, et al. Adjuvant treatment of resectable biliary tract cancer with cisplatin plus gemcitabine: A prospective single center phase II study. BMC Cancer 2018;18:72. Available at: https://www.ncbi.nlm.nih.gov/pubmed/29325521.

132. Overman MJ, Varadhachary GR, Kopetz S, et al. Phase II study of capecitabine and oxaliplatin for advanced adenocarcinoma of the small bowel and ampulla of Vater. J Clin Oncol 2009;27:2598–2603. Available at: https://www.ncbi.nlm.nih.gov/pubmed/19164203.

133. Andre T, Boni C, Mounedji-Boudiaf L, et al. Oxaliplatin, fluorouracil, and leucovorin as adjuvant treatment for colon cancer. N Engl J Med 2004;350:2343–2351. Available at: https://www.ncbi.nlm.nih.gov/pubmed/15175436.

134. Haller DG, Tabernero J, Maroun J, et al. Capecitabine plus oxaliplatin compared with fluorouracil and folinic acid as adjuvant therapy for stage III

Version 2.2026 © 2026 National Comprehensive Cancer Network© (NCCN©), All rights reserved. NCCN Guidelines® and this illustration may not be reproduced in any form without the express written permission of NCCN.

PLEASE NOTE that use of this NCCN Content is governed by the End-User License Agreement, and you MAY NOT distribute this Content or use it with any artificial intelligence model or tool.
Printed by Galya Basol Kochav on 2/14/2026 7:41:36 AM. Copyright © 2026 National Comprehensive Cancer Network, Inc. All Rights Reserved.

colon cancer. J Clin Oncol 2011;29:1465–1471. Available at: https://www.ncbi.nlm.nih.gov/pubmed/21383294.

135. Primrose JN, Fox RP, Palmer DH, et al. Capecitabine compared with observation in resected biliary tract cancer (BILCAP): a randomised, controlled, multicentre, phase 3 study. Lancet Oncol 2019;20:663–673. Available at: https://www.ncbi.nlm.nih.gov/pubmed/30922733.

136. Twelves C, Wong A, Nowacki MP, et al. Capecitabine as adjuvant treatment for stage III colon cancer. N Engl J Med 2005;352:2696–2704. Available at: https://www.ncbi.nlm.nih.gov/pubmed/15987918.

137. Conroy T, Hammel P, Hebbar M, et al. FOLFIRINOX or Gemcitabine as Adjuvant Therapy for Pancreatic Cancer. N Engl J Med 2018;379:2395–2406. Available at: https://www.ncbi.nlm.nih.gov/pubmed/30575490.

138. Klinkenbijl JH, Jeekel J, Sahmoud T, et al. Adjuvant radiotherapy and 5-fluorouracil after curative resection of cancer of the pancreas and periampullary region: phase III trial of the EORTC gastrointestinal tract cancer cooperative group. Ann Surg 1999;230:776–782; discussion 782–774. Available at: https://www.ncbi.nlm.nih.gov/pubmed/10615932.

139. Neoptolemos JP, Stocken DD, Friess H, et al. A randomized trial of chemoradiotherapy and chemotherapy after resection of pancreatic cancer. N Engl J Med 2004;350:1200–1210. Available at: https://www.ncbi.nlm.nih.gov/pubmed/15028824.

140. Von Hoff DD, Ervin T, Arena FP, et al. Increased survival in pancreatic cancer with nab-paclitaxel plus gemcitabine. N Engl J Med 2013;369:1691–1703. Available at: http://www.ncbi.nlm.nih.gov/pubmed/24131140.

141. Cunningham D, Chau I, Stocken DD, et al. Phase III randomized comparison of gemcitabine versus gemcitabine plus capecitabine in patients with advanced pancreatic cancer. J Clin Oncol 2009;27:5513–5518. Available at: http://www.ncbi.nlm.nih.gov/pubmed/19858379.

142. Oh DY, Ruth He A, Qin S, et al. Durvalumab plus Gemcitabine and Cisplatin in Advanced Biliary Tract Cancer. NEJM Evid 2022;1:EVIDoa2200015. Available at: https://www.ncbi.nlm.nih.gov/pubmed/38319896.

143. Conroy T, Desseigne F, Ychou M, et al. FOLFIRINOX versus gemcitabine for metastatic pancreatic cancer. N Engl J Med 2011;364:1817–1825. Available at: http://www.ncbi.nlm.nih.gov/pubmed/21561347.

144. Stein SM, James ES, Deng Y, et al. Final analysis of a phase II study of modified FOLFIRINOX in locally advanced and metastatic pancreatic cancer. Br J Cancer 2016;114:737–743. Available at: https://www.ncbi.nlm.nih.gov/pubmed/27022826.

145. Saltz LB, Clarke S, Diaz-Rubio E, et al. Bevacizumab in combination with oxaliplatin-based chemotherapy as first-line therapy in metastatic colorectal cancer: a randomized phase III study. J Clin Oncol 2008;26:2013–2019. Available at: https://www.ncbi.nlm.nih.gov/pubmed/18421054.

146. Fuchs CS, Marshall J, Mitchell E, et al. Randomized, controlled trial of irinotecan plus infusional, bolus, or oral fluoropyrimidines in first-line treatment of metastatic colorectal cancer: results from the BICC-C Study. J Clin Oncol 2007;25:4779–4786. Available at: https://www.ncbi.nlm.nih.gov/pubmed/17947725.

147. Falcone A, Ricci S, Brunetti I, et al. Phase III trial of infusional fluorouracil, leucovorin, oxaliplatin, and irinotecan (FOLFOXIRI) compared with infusional fluorouracil, leucovorin, and irinotecan (FOLFIRI) as first-line treatment for metastatic colorectal cancer: the Gruppo Oncologico Nord Ovest. J Clin Oncol 2007;25:1670–1676. Available at: https://www.ncbi.nlm.nih.gov/pubmed/17470860.

148. de Gramont A, Figer A, Seymour M, et al. Leucovorin and fluorouracil with or without oxaliplatin as first-line treatment in advanced colorectal cancer. J Clin Oncol 2000;18:2938–2947. Available at: https://www.ncbi.nlm.nih.gov/pubmed/10944126.

Version 2.2026 © 2026 National Comprehensive Cancer Network© (NCCN©), All rights reserved. NCCN Guidelines® and this illustration may not be reproduced in any form without the express written permission of NCCN.

PLEASE NOTE that use of this NCCN Content is governed by the End-User License Agreement, and you MAY NOT distribute this Content or use it with any artificial intelligence model or tool.
Printed by Galya Basol Kochav on 2/14/2026 7:41:36 AM. Copyright © 2026 National Comprehensive Cancer Network, Inc. All Rights Reserved.

149. Van Cutsem E, Twelves C, Cassidy J, et al. Oral capecitabine compared with intravenous fluorouracil plus leucovorin in patients with metastatic colorectal cancer: results of a large phase III study. J Clin Oncol 2001;19:4097–4106. Available at: https://www.ncbi.nlm.nih.gov/pubmed/11689577.

150. Cunningham D, Lang I, Marcuello E, et al. Bevacizumab plus capecitabine versus capecitabine alone in elderly patients with previously untreated metastatic colorectal cancer (AVEX): an open-label, randomised phase 3 trial. Lancet Oncol 2013;14:1077–1085. Available at: https://www.ncbi.nlm.nih.gov/pubmed/24028813.

151. Marabelle A, Le DT, Ascierto PA, et al. Efficacy of pembrolizumab in patients with noncolorectal high microsatellite instability/mismatch repair-deficient cancer: Results from the phase II KEYNOTE-158 study. J Clin Oncol 2020;38:1–10. Available at: https://www.ncbi.nlm.nih.gov/pubmed/31682550.

152. Lenz HJ, Van Cutsem E, Luisa Limon M, et al. First-line nivolumab plus low-dose ipilimumab for microsatellite instability-high/mismatch repair-deficient metastatic colorectal cancer: The phase II CheckMate 142 study. J Clin Oncol 2022;40:161–170. Available at: https://www.ncbi.nlm.nih.gov/pubmed/34637336.

153. Overman MJ, Lonardi S, Wong KYM, et al. Durable clinical benefit with nivolumab plus ipilimumab in DNA mismatch repair-deficient/microsatellite instability-high metastatic colorectal cancer. J Clin Oncol 2018;36:773–779. Available at: https://www.ncbi.nlm.nih.gov/pubmed/29355075.

154. Drilon A, Laetsch TW, Kummar S, et al. Efficacy of larotrectinib in TRK fusion-positive cancers in adults and children. N Engl J Med 2018;378:731–739. Available at: https://www.ncbi.nlm.nih.gov/pubmed/29466156.

155. Doebele RC, Drilon A, Paz-Ares L, et al. Entrectinib in patients with advanced or metastatic NTRK fusion-positive solid tumours: integrated analysis of three phase 1-2 trials. Lancet Oncol 2020;21:271–282. Available at: https://www.ncbi.nlm.nih.gov/pubmed/31838007.

156. Solomon BJ, Drilon A, Lin JJ, et al. 1372P Repotrectinib in patients (pts) with NTRK fusion-positive (NTRK+) advanced solid tumors, including NSCLC: Update from the phase I/II TRIDENT-1 trial. Annals of Oncology 2023;34:S787–S788. Available at: https://doi.org/10.1016/j.annonc.2023.09.2405.

157. Subbiah V, Wolf J, Konda B, et al. Tumour-agnostic efficacy and safety of selpercatinib in patients with RET fusion-positive solid tumours other than lung or thyroid tumours (LIBRETTO-001): a phase 1/2, open-label, basket trial. Lancet Oncol 2022;23:1261–1273. Available at: https://www.ncbi.nlm.nih.gov/pubmed/36108661.

158. Salama AKS, Li S, Macrae ER, et al. Dabrafenib and trametinib in patients with tumors with BRAF(V600E) mutations: results of the NCI-MATCH Trial Subprotocol H. J Clin Oncol 2020;38:3895–3904. Available at: https://www.ncbi.nlm.nih.gov/pubmed/32758030.

159. Subbiah V, Lassen U, Elez E, et al. Dabrafenib plus trametinib in patients with BRAF(V600E)-mutated biliary tract cancer (ROAR): a phase 2, open-label, single-arm, multicentre basket trial. Lancet Oncol 2020;21:1234–1243. Available at: https://www.ncbi.nlm.nih.gov/pubmed/32818466.

160. Boeck S, Vehling-Kaiser U, Waldschmidt D, et al. Erlotinib 150 mg daily plus chemotherapy in advanced pancreatic cancer: an interim safety analysis of a multicenter, randomized, cross-over phase III trial of the 'Arbeitsgemeinschaft Internistische Onkologie'. Anticancer Drugs 2010;21:94–100. Available at: https://www.ncbi.nlm.nih.gov/pubmed/19770635.

161. Xiong HQ, Varadhachary GR, Blais JC, et al. Phase 2 trial of oxaliplatin plus capecitabine (XELOX) as second-line therapy for patients with advanced pancreatic cancer. Cancer 2008;113:2046–2052. Available at: http://www.ncbi.nlm.nih.gov/pubmed/18756532.

162. Wang-Gillam A, Li CP, Bodoky G, et al. Nanoliposomal irinotecan with fluorouracil and folinic acid in metastatic pancreatic cancer after previous gemcitabine-based therapy (NAPOLI-1): a global, randomised,

Version 2.2026 © 2026 National Comprehensive Cancer Network© (NCCN©), All rights reserved. NCCN Guidelines® and this illustration may not be reproduced in any form without the express written permission of NCCN.

PLEASE NOTE that use of this NCCN Content is governed by the End-User License Agreement, and you MAY NOT distribute this Content or use it with any artificial intelligence model or tool.
Printed by Galya Basol Kochav on 2/14/2026 7:41:36 AM. Copyright © 2026 National Comprehensive Cancer Network, Inc. All Rights Reserved.

open-label, phase 3 trial. Lancet 2016;387:545–557. Available at: https://www.ncbi.nlm.nih.gov/pubmed/26615328.

163. Gill S, Ko YJ, Cripps C, et al. PANCREOX: A randomized phase III study of fluorouracil/leucovorin with or without oxaliplatin for second-Line advanced pancreatic cancer in patients who have received gemcitabine-based chemotherapy. J Clin Oncol 2016;34:3914–3920. Available at: https://www.ncbi.nlm.nih.gov/pubmed/27621395.

164. Yoo C, Kim KP, Kim I, et al. Final results from the NIFTY trial, a phase IIb, randomized, open-label study of liposomal Irinotecan (nal-IRI) plus fluorouracil (5-FU)/leucovorin (LV) in patients (pts) with previously treated metastatic biliary tract cancer (BTC). Ann Oncol 2022;33:S565. Available at: https://doi.org/10.1016/j.annonc.2022.07.083.

165. Vogel A, Wenzel P, Folprecht G, et al. Nal-IRI and 5-FU/LV compared to 5-FU/LV in patients with cholangio- and gallbladder carcinoma previously treated with gemcitabine-based therapies (NALIRICC – AIO-HEP-0116). Ann Oncol 2022;33:S563–S564. Available at: https://doi.org/10.1016/j.annonc.2022.07.081.

166. Neuzillet C, Hentic O, Rousseau B, et al. FOLFIRI regimen in metastatic pancreatic adenocarcinoma resistant to gemcitabine and platinum-salts. World J Gastroenterol 2012;18:4533–4541. Available at: https://www.ncbi.nlm.nih.gov/pubmed/22969226.

167. Zaniboni A, Aitini E, Barni S, et al. FOLFIRI as second-line chemotherapy for advanced pancreatic cancer: a GISCAD multicenter phase II study. Cancer Chemother Pharmacol 2012;69:1641–1645. Available at: https://www.ncbi.nlm.nih.gov/pubmed/22576338.

168. Chiorean EG, Guthrie KA, Philip PA, et al. Randomized phase II study of PARP inhibitor ABT-888 (Veliparib) with modified FOLFIRI versus FOLFIRI as second-line treatment of metastatic pancreatic cancer: SWOG S1513. Clin Cancer Res 2021;27:6314–6322. Available at: https://www.ncbi.nlm.nih.gov/pubmed/34580114.

169. Mizrahi JD, Gunchick V, Mody K, et al. Multi-institutional retrospective analysis of FOLFIRI in patients with advanced biliary tract cancers. World J Gastrointest Oncol 2020;12:83–91. Available at: https://www.ncbi.nlm.nih.gov/pubmed/31966916.

170. Chiorean EG, Von Hoff DD, Tabernero J, et al. Second-line therapy after nab-paclitaxel plus gemcitabine or after gemcitabine for patients with metastatic pancreatic cancer. Br J Cancer 2016;115:e13. Available at: https://www.ncbi.nlm.nih.gov/pubmed/27657342.

171. Yoo C, Hwang JY, Kim JE, et al. A randomised phase II study of modified FOLFIRI.3 vs modified FOLFOX as second-line therapy in patients with gemcitabine-refractory advanced pancreatic cancer. Br J Cancer 2009;101:1658–1663. Available at: http://www.ncbi.nlm.nih.gov/pubmed/19826418.

172. Tsavaris N, Kosmas C, Skopelitis H, et al. Second-line treatment with oxaliplatin, leucovorin and 5-fluorouracil in gemcitabine-pretreated advanced pancreatic cancer: A phase II study. Invest New Drugs 2005;23:369–375. Available at: https://www.ncbi.nlm.nih.gov/pubmed/16012797.

173. Novarino A, Satolli MA, Chiappino I, et al. Oxaliplatin, 5-fluorouracil, and leucovorin as second-line treatment for advanced pancreatic cancer. Am J Clin Oncol 2009;32:44–48. Available at: https://www.ncbi.nlm.nih.gov/pubmed/19194124.

174. Azmy A, Abdelwahab S, Yassen M. Oxaliplatin and bolus-modulated 5-fluorouracil as a second-line treatment for advanced pancreatic cancer: Can bolus regimens replace FOLFOX when considered for second line? ISRN Oncol 2013;2013:358538. Available at: https://www.ncbi.nlm.nih.gov/pubmed/23533808.

175. Lamarca A, Palmer DH, Wasan HS, et al. Second-line FOLFOX chemotherapy versus active symptom control for advanced biliary tract cancer (ABC-06): a phase 3, open-label, randomised, controlled trial. Lancet Oncol 2021;22:690–701. Available at: https://www.ncbi.nlm.nih.gov/pubmed/33798493.

176. Pelzer U, Schwaner I, Stieler J, et al. Best supportive care (BSC) versus oxaliplatin, folinic acid and 5-fluorouracil (OFF) plus BSC in

Version 2.2026 © 2026 National Comprehensive Cancer Network© (NCCN©), All rights reserved. NCCN Guidelines® and this illustration may not be reproduced in any form without the express written permission of NCCN.

PLEASE NOTE that use of this NCCN Content is governed by the End-User License Agreement, and you MAY NOT distribute this Content or use it with any artificial intelligence model or tool.
Printed by Galya Basol Kochav on 2/14/2026 7:41:36 AM. Copyright © 2026 National Comprehensive Cancer Network, Inc. All Rights Reserved.

patients for second-line advanced pancreatic cancer: a phase III-study from the German CONKO-study group. Eur J Cancer 2011;47:1676–1681. Available at: http://www.ncbi.nlm.nih.gov/pubmed/21565490.

177. O'Reilly EM, Lee JW, Zalupski M, et al. Randomized, multicenter, phase II trial of gemcitabine and cisplatin with or without veliparib in patients with pancreas adenocarcinoma and a germline BRCA/PALB2 mutation. J Clin Oncol 2020;38:1378–1388. Available at: https://www.ncbi.nlm.nih.gov/pubmed/31976786.

178. Berton D, Banerjee SN, Curigliano G, et al. Antitumor activity of dostarlimab in patients with mismatch repair-deficient/microsatellite instability–high tumors: A combined analysis of two cohorts in the GARNET study. J Clin Oncol 2021;39:2564–2564. Available at: https://ascopubs.org/doi/abs/10.1200/JCO.2021.39.15_suppl.2564.

179. Meric-Bernstam F, Makker V, Oaknin A, et al. Efficacy and Safety of Trastuzumab Deruxtecan in Patients With HER2-Expressing Solid Tumors: Primary Results From the DESTINY-PanTumor02 Phase II Trial. J Clin Oncol 2024;42:47–58. Available at: https://www.ncbi.nlm.nih.gov/pubmed/37870536.

180. Ohba A, Morizane C, Kawamoto Y, et al. Trastuzumab Deruxtecan in Human Epidermal Growth Factor Receptor 2-Expressing Biliary Tract Cancer (HERB; NCCH1805): A Multicenter, Single-Arm, Phase II Trial. J Clin Oncol 2024;42:3207–3217. Available at: https://www.ncbi.nlm.nih.gov/pubmed/39102634.

181. Siena S, Di Bartolomeo M, Raghav K, et al. Trastuzumab deruxtecan (DS-8201) in patients with HER2-expressing metastatic colorectal cancer (DESTINY-CRC01): a multicentre, open-label, phase 2 trial. Lancet Oncol 2021;22:779–789. Available at: https://www.ncbi.nlm.nih.gov/pubmed/33961795.

Version 2.2026 © 2026 National Comprehensive Cancer Network© (NCCN©), All rights reserved. NCCN Guidelines® and this illustration may not be reproduced in any form without the express written permission of NCCN.